

# "Dynamic External Fixation for Proximal Interphalangeal Fracture-Dislocations"

Curtis M. Henn, MD,\* Steve K. Lee, MD,<sup>†</sup> and Scott W. Wolfe, MD\*

Proximal interphalangeal fracture-dislocations and pilon fractures of the middle phalanx represent a conundrum for hand surgeons. Goals of treatment are to: (1) maintain a stable congruent joint, (2) reduce intra-articular step-offs, and (3) prevent stiffness. Because the fragments of the middle phalanx are small, internal fixation is difficult and often impossible. Options other than internal fixation include hemi-hamate arthroplasty, volar plate arthroplasty, extension block pinning, and dynamic external fixation. Techniques for dynamic external fixation of the digit for the treatment of proximal interphalangeal fracture-dislocations and pilon fractures have evolved since first reported in 1946 by Robertson et al. In 1989, Slade et al developed a fixator that uses 3 Kirschner wires and dental rubber bands. Several groups have since published favorable outcomes using this technique. We have used this technique for the past 10 years at our institution and have had similar encouraging results. The present article describes the indications, operative technique, and postoperative protocol used by the authors. A brief review of results and complications are presented, and 2 illustrative case examples are provided.

Oper Tech Orthop 22:142-150 © 2012 Elsevier Inc. All rights reserved.

**KEYWORDS** force-coupled splint, dynamic external fixation, PIP fracture/dislocations, pilon fractures

## Background

Unstable proximal interphalangeal (PIP) fracture-dislocations and pilon fractures of the middle phalanx remain challenging injuries to treat. Goals of treatment are to alleviate pain, prevent posttraumatic arthritis by restoring a congruent joint surface, and optimize functional outcome by maintaining stable range of motion. Many treatments have been described with varying results, including extension block splinting,<sup>1</sup> extension block pinning,<sup>2</sup> open reduction and internal fixation (ORIF),<sup>3,4</sup> hemi-hamate arthroplasty,<sup>5,6</sup> volar plate arthroplasty,<sup>7</sup> and dynamic external fixation.<sup>8-10</sup>

Injury characteristics and surgeon experience often dictate the treatment chosen. Fracture-dislocations that have a congruent joint after closed reduction and are stable through 30-90° of flexion may be successfully treated with extension block splinting. If a congruent joint reduction cannot be ob-

tained by closed means, an ORIF may be chosen if there is a single large fragment or an arthroplasty may be necessary if there is comminution. Finally, if a congruent reduction can be obtained by closed reduction but the joint or fracture is dynamically unstable, a dynamic external fixator, ORIF, or a combination technique is required.

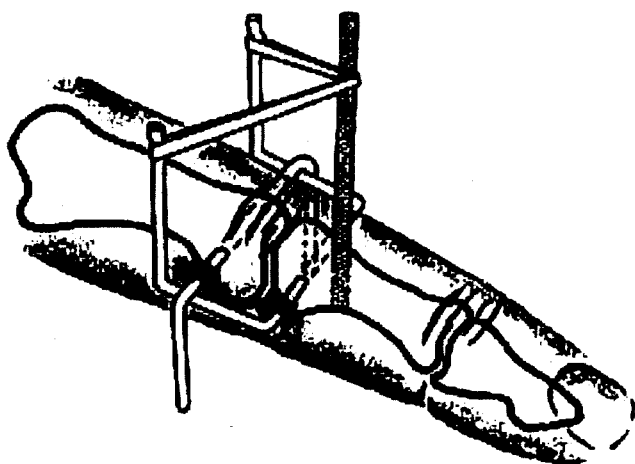
The first reference to external fixation for the treatment of PIP fracture-dislocations was in 1946 when Robertson, Cawley, and Faris described a triplane external fixation device.<sup>11</sup> This system uses 3 pins, 1 in the proximal phalanx and 2 in the middle phalanx. It used constant traction on the 3 pins via attachments to a banjo-type splint in 3 different directions to maintain a reduced joint. The article reported 7 cases treated in this manner with maintenance of reduction, bony union, and "good" functional result of all 7 cases. Only 1 case achieved flexion of 90°, and 3/7 cases had an extension lag of 5°.

Because the PIP joint is prone to stiffness with immobilization, Agee<sup>8</sup> developed a technique with Kirschner (K-) wires and rubber bands that enabled early range of motion of the injured digit while maintaining a congruent joint. This technique used 3 K-wires, 2 in the middle phalanx and 1 in the proximal phalanx. One of the middle phalangeal K-wires was oriented vertically, dorsal to volar (Fig. 1). Agee<sup>12</sup> reported 18 cases treated in this manner from 1978 to 1987.

\*Hand and Upper Extremity Service, Department of Orthopedic Surgery, Hospital for Special Surgery, New York, NY.

<sup>†</sup>Orthopaedic Surgery Weill Cornell Medical College Hospital for Special Surgery, New York, NY.

Address reprint requests to Curtis M. Henn, MD, Hand and Upper Extremity Service, Department of Orthopedic Surgery, Hospital for Special Surgery, New York, NY. E-mail: hennnc@hss.edu



The ideal dynamic external fixator should be equally effective at maintaining joint reduction as allowing range of motion. It should be inexpensive and easy to apply. For these reasons, we favor the construct originally described by Slade et al<sup>10</sup> for dynamic external fixation of unstable PIP fracture-dislocations. This device consisting of 3 K-wires and dental rubber bands is inexpensive and can be easily applied. It maintains constant traction throughout range of motion, while exerting a translational moment on the middle phalanx to maintain reduction in the sagittal plane for dorsal fracture dislocations. The importance of the latter goal was underscored by Slade's cadaveric research, demonstrating that devices that provide traction alone require 300% more force to keep the joint reduced than devices that use a mechanism to reduce the dorsal translation moment. A middle pin in this device is positioned to apply the needed sagittal restraint, which in turn minimizes overdistraction of the joint.<sup>10</sup>

## Indications

Many techniques can be used in treating unstable PIP fracture-dislocations, and accordingly, we allow the injury char-

acteristics and presentation to dictate our treatment. The main indication for dynamic external fixation is a PIP fracture-dislocation that can be reduced with closed methods but is dynamically unstable. Generally speaking, fractures that involve >30% of the articular surface are at risk for instability, whereas fractures involving 50% or more are nearly always unstable.<sup>27</sup> For the fixator to be successful, a congruent reduction must be obtainable by a combination of traction and/or translation. Further, the reduction must be able to be maintained with traction and/or translation throughout the full range of motion.

Depending on the fracture characteristics and the alignment of fracture fragments after closed reduction, the dynamic fixator may be used alone or in conjunction with volar plate arthroplasty, hemi-hamate arthroplasty, ORIF, or percutaneous pinning. In dorsal fracture-dislocations, the palmar lip is typically fractured. If there is significant comminution and closed reduction does not adequately align the fragments, volar plate arthroplasty may be performed in addition to the application of a dynamic external fixation device. Hemi-hamate arthroplasty with or without dynamic external fixation can also be performed in select cases. If a single large fragment is avulsed off of the palmar lip, we will perform either a percutaneous pinning or ORIF in addition to application of the fixator. These procedures restore the middle phalanx palmar buttress, which enhances dynamic stability of the joint.

Dorsal lip fractures with palmar subluxation can also be successfully treated with dynamic external fixation. Large dorsal fragments may be pinned percutaneously, or the central slip of the extensor tendon may be repaired to the fracture bed if there is significant comminution. The dynamic fixator then allows early range of motion of the joint by neutralizing palmar translational forces.

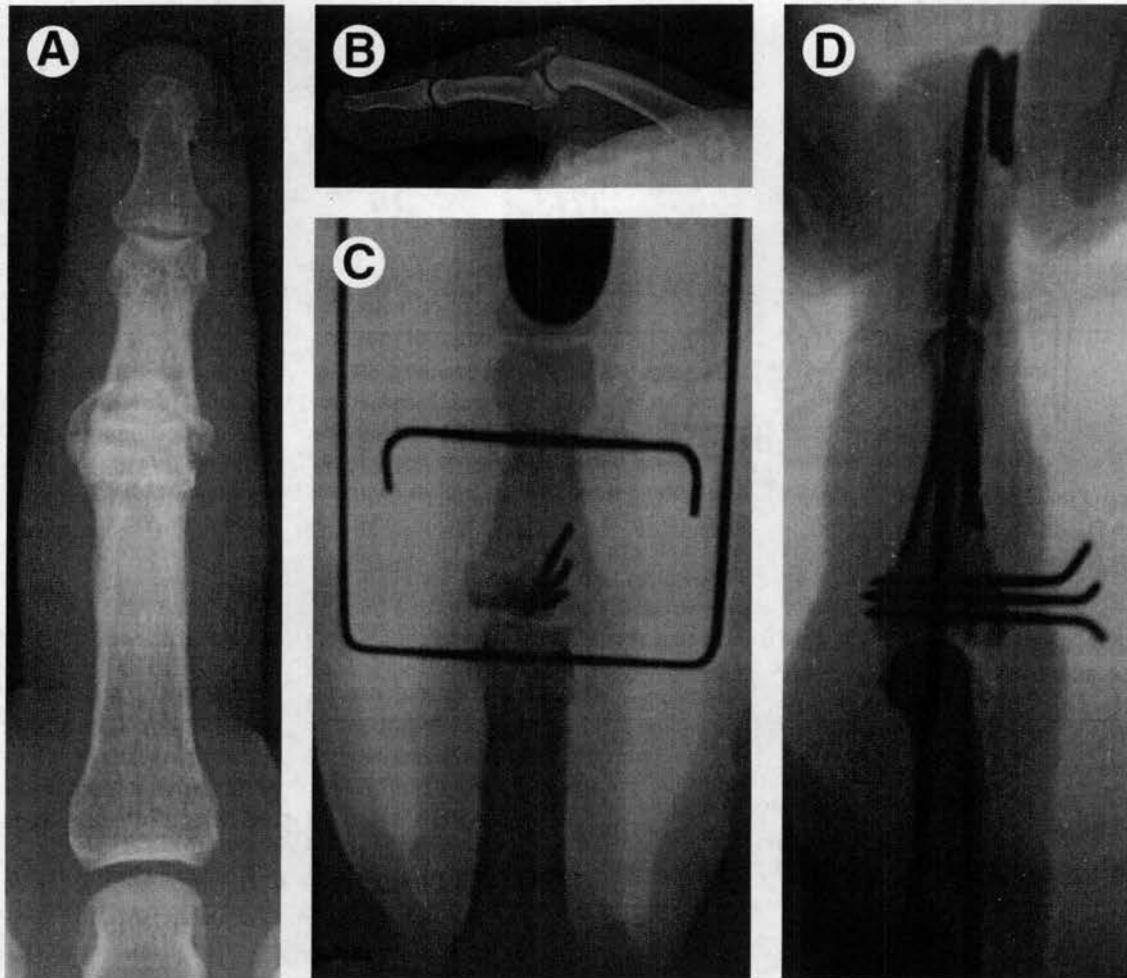
Fractures that disrupt both the dorsal and palmar cortices of the middle phalanx were defined by Stern et al<sup>28</sup> as "pilon" fractures. These fractures are typically characterized by significant articular comminution and impaction of the central fragments into the metaphysis of the middle phalanx.

We use dynamic external fixation to treat these injuries (Fig. 2). The immediate motion allowed by the fixator serves to compensate for a less than anatomic articular reduction. If traction and translation alone do not restore the cup shape of the middle phalanx and the fracture contains large enough fragments, we will use percutaneous pinning to better improve the joint surface. Early range of motion, though, is more important than anatomic joint surface reduction in achieving adequate clinical results.<sup>27</sup>

Dynamic external fixation devices can also be used to treat unstable fracture-dislocations of the DIP and metacarpophalangeal joints of the hand, as has been previously described with a hinged fixator.<sup>14</sup> If neighboring digits are involved, then the fixator may not be the best treatment choice.

## Technique

We prefer the original technique as described by Slade in 1990<sup>9</sup> and first published in 2000.<sup>10</sup> It has subsequently been



**Figure 2** Anteroposterior (AP) (A) and lateral (B) radiographs of a middle phalangeal pilon fracture. AP (C) and lateral (D) radiographs after application of a dynamic external fixator and percutaneous pinning of the middle phalanx pilon fracture.

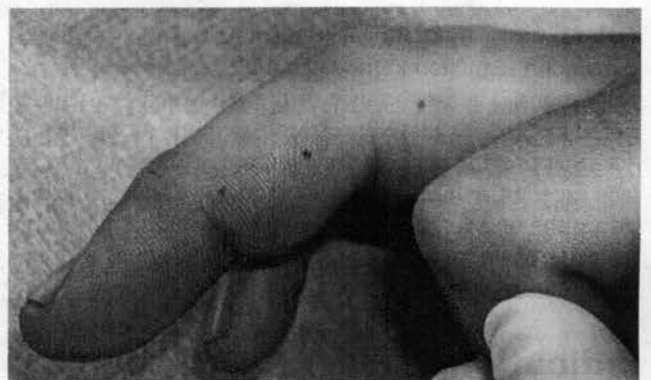
described in various outcome studies<sup>29,30</sup> and in Green's *Operative Hand Surgery*.<sup>31</sup> As an overview, the technique uses 3 0.045-inch (1.4-mm) K-wires inserted parallel to each other and perpendicular to the long axis of the finger. The wires are then bent and rubber bands applied.

After the induction of regional anesthesia and application of a nonsterile brachial tourniquet, the affected extremity is prepped and draped in a sterile fashion. A closed reduction is then performed. If a closed reduction is not possible, then other means of gaining reduction should be attempted. Percutaneous K-wire manipulation of the fragments may be successful in realigning the joint surface and disimpacting articular fragments in the acute situation, but fractures >7- to 10-day old probably require open reduction. It is important that the surgeon attempt to respect the collateral ligaments and the capsular sleeve to the extent possible. Disruption of the collateral ligaments increases the possibility of overdistraction. Open reduction does not preclude the use of the fixator. Once it is confirmed that a reduction can be obtained and held through a range of motion, we proceed with the application of the fixator.

First, a minifluoroscopy unit is used to identify the center of rotation of the proximal phalangeal head, the center

of rotation of the middle phalangeal head, and a point just distal to the fracture in the intact metadiaphyseal region of the middle phalanx. The skin is marked at these locations (Fig. 3).

Double-ended 9-inch 0.045-inch K-wires are essential for the procedure. The first K-wire is placed at the center of

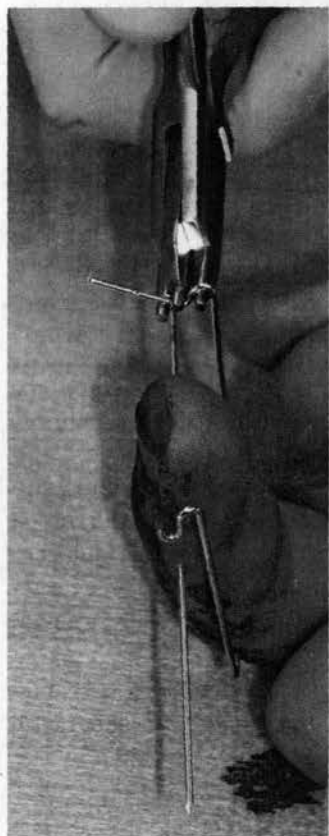


**Figure 3** Three entry points are identified on lateral fluoroscopy and marked on the skin with a marking pen as shown.

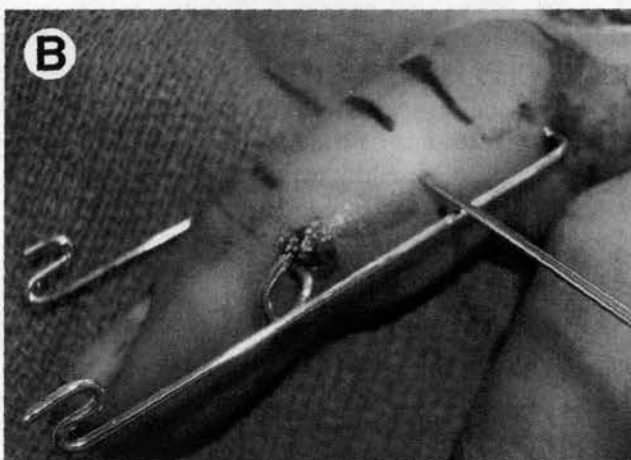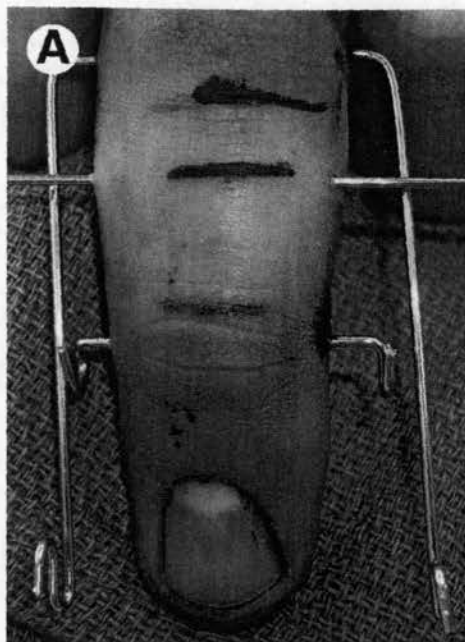
rotation of the proximal phalangeal head and confirmed on lateral fluoroscopy. The wire is then advanced through the opposite cortex and skin. It is paramount that there is an even amount of wire on each side of the finger so that there will be an adequate amount of wire after bending to hold the rubber bands. The second K-wire is similarly advanced through the center of rotation of the head of the middle phalanx and through the other side. It is vital that the proximal wire be placed as close as possible to the precise center of rotation to ensure a constant force from the fixator throughout range of motion.

The proximal K-wire is then bent 90° with pliers or a heavy needle driver and is rotated so the ends of the wire point distally along the axis of the digit. The proximal wire passes volarly to the distal K-wire. The distal ends of the proximal K-wire are then fashioned into dorsal hooks using a small 3-point bender (Fig. 4). The distal bends should be at the level of the fingertip to leave enough room to place the rubber bands. The distal K-wire is then bent 90° distally, and hooks are again fashioned using the 3-point bender. The distance between the proximal and distal K-wires should be approximately 2.5 cm, which optimizes distraction force by the rubber bands while avoiding overdistraction.

Finally, the third midaxial K-wire, also call the "reduction" K-wire, is passed through the middle phalanx distal to the fracture and parallel in the frontal plane to the first 2 K-wires.



**Figure 4** The ends of the proximal wire are bent distal along the axis of the digit. The tips of the proximal wire are then fashioned into hooks with a 3-point bender as shown.



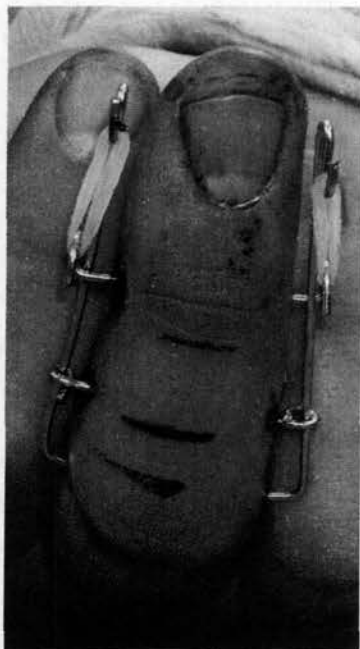**Figure 5** Dorsal (A) and lateral (B) views of the positioning of the third K-wire. The proximal and distal K-wires are already bent into proper orientation.

This wire is initially placed dorsal to the bent proximal K-wire (Fig. 5); but depending on the middle phalanx position on lateral fluoroscopy, the wire can be used to optimally reduce the phalanx by passing it over or under the proximal wire. The third wire effectively applies a volar- or, less commonly, a dorsal-directed translational force to the middle phalanx, keeping the joint reduced and minimizing the amount of traction needed to maintain the reduction.

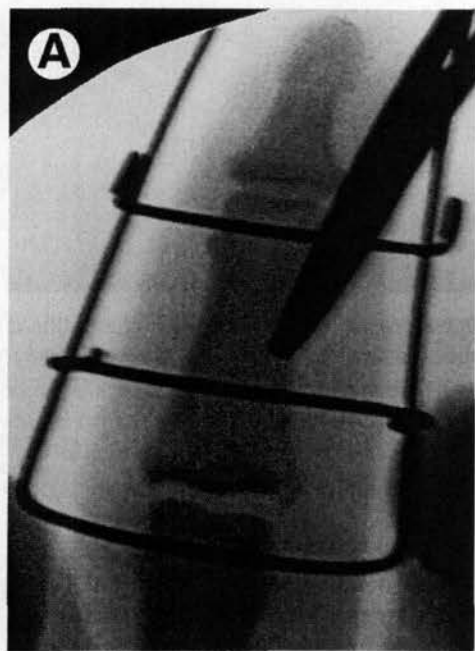
It is vital that all 3 K-wires are passed under the guidance of lateral fluoroscopic imaging to ensure the wires are midaxial. This minimizes the soft tissue irritation, as palmar and dorsal skin forces are balanced in this area.

The third K-wire is cut short and bent around the proximal K-wire on both sides of the finger. Dental rubber bands are then applied between the proximal and distal K-wires with a smooth forceps (Fig. 6). Typically, 2 or 3 rubber bands apply adequate traction. The 2 initial wires span the joint, and a

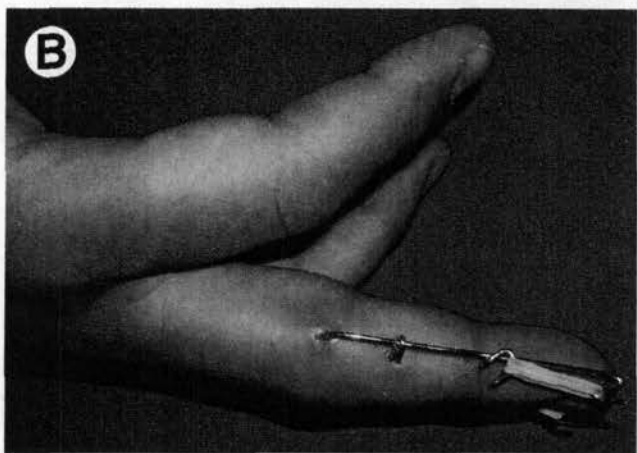
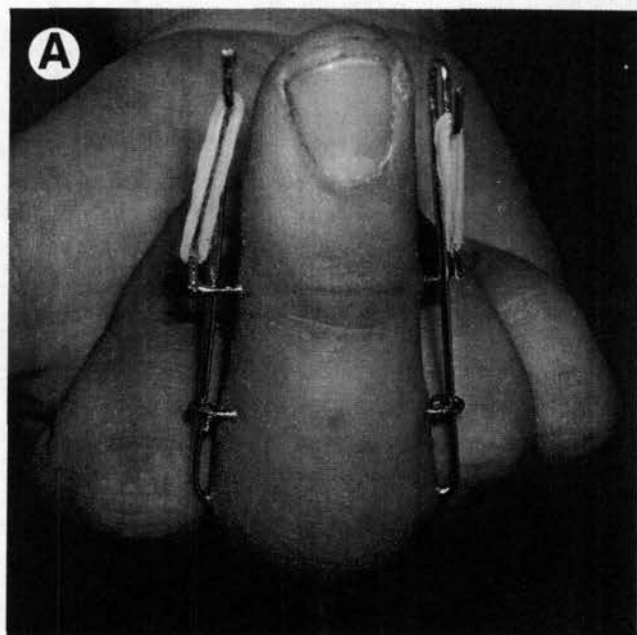




**Figure 6** The dynamic external fixator is complete when the rubber bands are placed as shown in this photo and the third K-wire has been bent around the proximal K-wire as shown.



**Figure 7** Final AP (A) and lateral (B) fluoroscopic images are obtained, showing adequate reduction and placement of K-wires.



**Figure 8** Clinical photographs taken at 1 week in maximal active flexion (A) and extension (B).

distraction force is generated by the rubber bands at the joint. This traction force then maintains reduction through ligamentotaxis.

For the treatment of pilon fractures of the base of the middle phalanx, one of the authors (S) uses an identical procedure but does not use a third "reduction" K-wire. This construct only uses 2 K-wires and only traction for reduction, with or without ORIF or percutaneous pinning of the fracture (Fig. 2).

Once the fixator is assembled, final anteroposterior and lateral fluoroscopic images are obtained to confirm adequate placement of all pins (Fig. 7). The finger is then taken through full range of motion under live lateral fluoroscopy to confirm reduction. Overdistraction is carefully assessed, particularly if an ORIF was performed. The pin sites are then dressed with petroleum gauze followed by a soft bandage.

## Postoperative Protocol

Patients are started on a gentle range of motion regimen immediately postoperatively after 2 or 3 days of elevation and rest. Formal hand therapy starts 1 week after application of the fixator (Fig. 8). Therapy includes both active and passive range of motion at both interphalangeal joints as well as the metacarpophalangeal joint. Therapy usually lasts for 2-3 months.

Lateral radiographs are obtained at the first postoperative visit. If the joint is not congruent, additional rubber bands may be added until the joint is reduced. Alternatively, if there is overdistraction, some of the rubber bands may be removed. At 4 weeks, repeat lateral radiographs are obtained to evaluate for healing. If the fracture appears healed, a second lateral radiograph is obtained with the rubber bands removed to confirm reduction. If the fracture is healed and the joint reduced without traction, the frame is removed. If it is not healed or the joint is subluxated, radiographs are checked every 1-2 weeks thereafter.

Pin sites are kept clean with daily or twice daily swabs of peroxide. Alternatively, the pin sites may be kept completely dry, as is the protocol for one of the authors (SKL). A custom splint is helpful to prevent accidental damage to the fixator. Patients are allowed to shower if the pin sites remain benign. Pin-site infections are treated with oral antibiotics and typically resolve once the frame is removed.

## Results

In 2007, our institution reported our results of this technique.<sup>30</sup> In 8 patients treated at our institution at an average follow-up of 26 months, average PIP range of motion was 1-89° of flexion. Grip strength was 92% of the unaffected side, and average visual analog pain scale was 0.6. Radiographic evaluation showed congruent joints in all patients at final follow-up. However, 2 patients had evidence of early arthritis, and an additional 3 patients showed intra-articular step-off of 1 mm or greater.

Our results were similar to other published outcome studies that used a nearly identical dynamic fixator.<sup>26,29,32,33</sup> All 4 studies used 3 K-wires, axial rubber bands, and similar postoperative protocols. A total of 55 patients in all 4 studies had an average of 85° of active PIP range of motion at an average of 1- to 2-year follow-up. None of these studies attempted to quantify pain, but 1 patient in the Suzuki study had pain "sometimes" and no patients in the De Smet study "experienced more than an occasional mild pain and cold intoler-

ance." All 26 patients in the Ruland series returned to their previous level of activity and duty in the military.

The most common complication reported is pin-site infection. Infection rates varied from 13% to 25%. Only 2 of these infections required premature removal of the fixator, and both of these cases maintained a congruent joint after removal.<sup>32</sup> Similar to our results, Ruland et al<sup>29</sup> found that intra-articular step-offs remained after treatment with the dynamic fixator, but none of their 26 patients showed evidence of arthritis at an average of 16-month follow-up. Two patients from these series required extensor tendon tenolysis several months after fixator removal.<sup>29,33</sup> Lastly, 1 of 26 patients in the Ruland series and 1 of 8 patients in the De Smet series developed angular deformities. In our series, 2 of 8 patients had angular deformities at final follow-up, but 1 patient's deformity predated the PIP injury.

### Case 1

A 32-year-old male sustained a PIP fracture-dislocation of his right index finger while playing basketball. Radiographs confirmed the fracture-dislocation and showed an impaction injury to >50% of the middle phalangeal articular surface (Fig. 9). A closed reduction and application of dynamic external fixation were performed in the operating room. Active and passive range of motion commenced immediately postoperatively, and the patient was enrolled in formal hand therapy within 1 week postoperatively. Radiographs 3 days postoperatively confirmed concentric reduction.

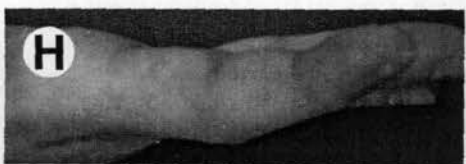
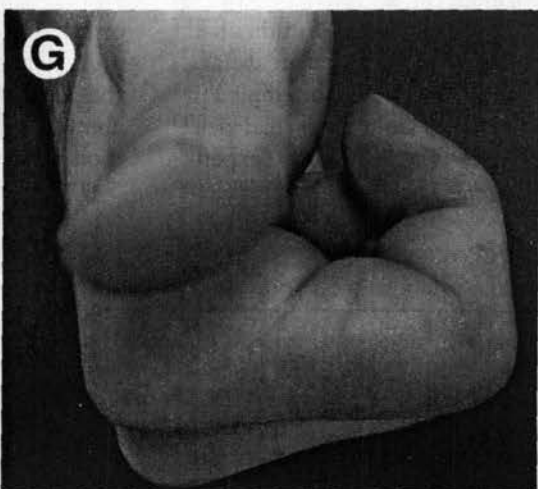

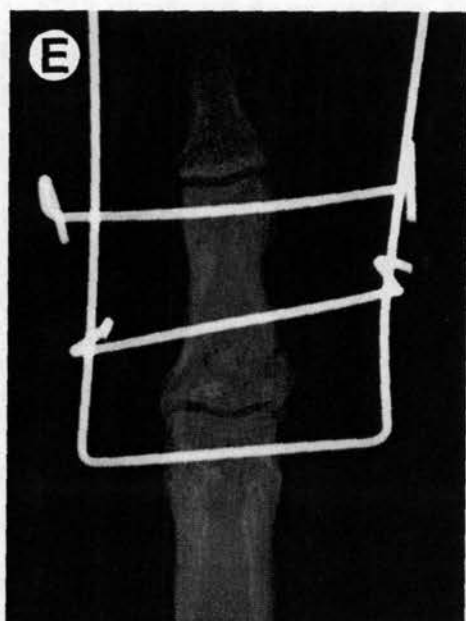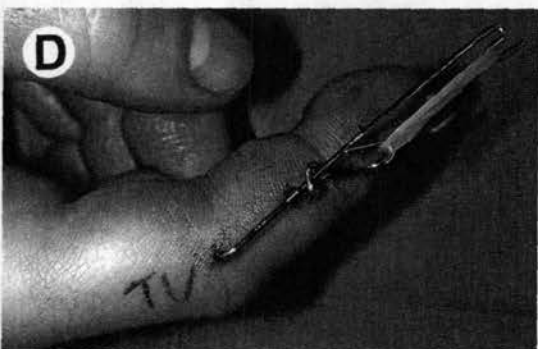
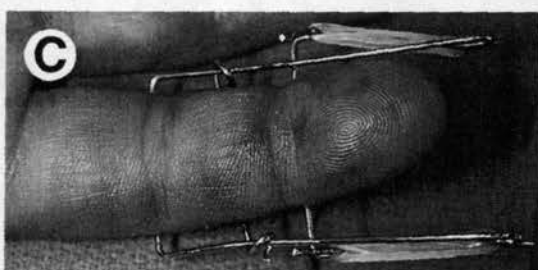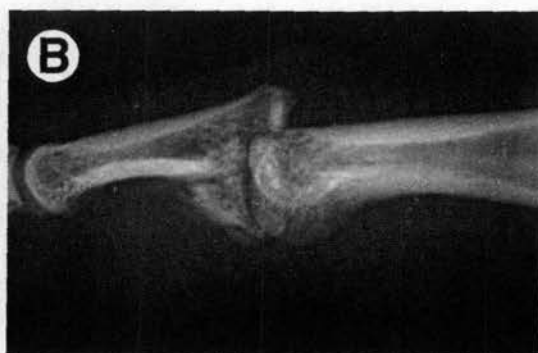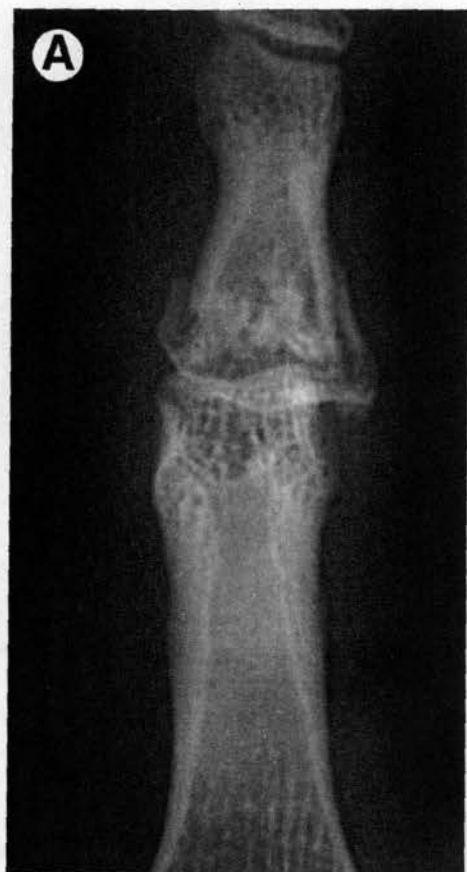By 7 weeks, the fracture had healed, and the fixator was removed. By 4 months postoperatively, the patient attained a PIP range of motion from 10 to 90° of flexion. Final follow-up radiographs taken 11 months postoperatively showed a concentric reduction, healed fracture with a mild joint step-off, and mild arthritic change.

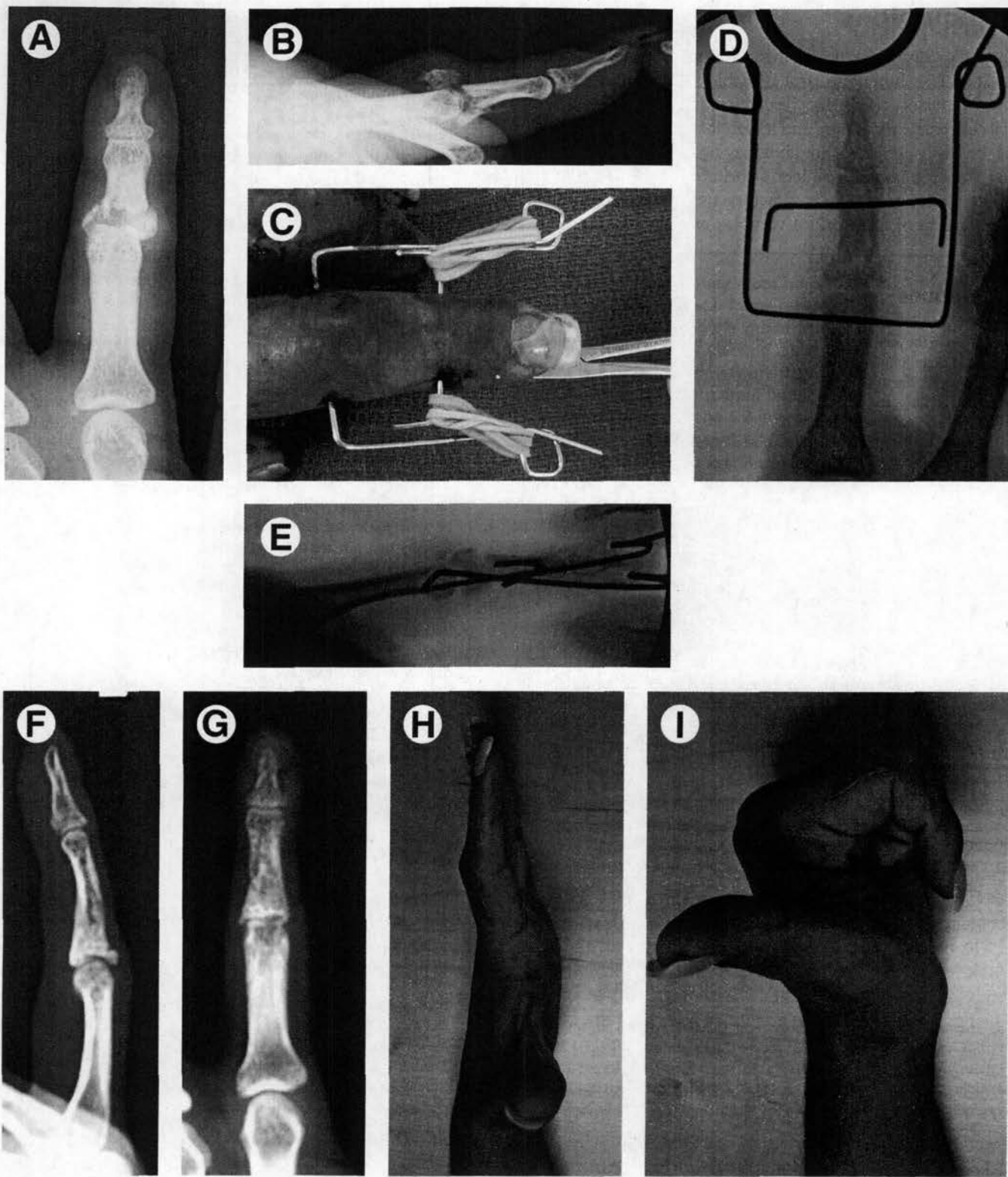### Case 2

A 26-year-old female sustained a pilon fracture of the base of her left index finger in a motor vehicle accident. Radiographs showed extreme disruption of the PIP articular surface and displacement of the articular fragments (Fig. 10). The patient was taken to the operating room and a 2 K-wire dynamic external fixator was applied.

At 2 months postoperatively, the fracture had healed and the fixator was removed. Radiographs at final follow-up showed a mostly concentric joint and healed fracture. At 10 months after the injury, her PIP active range of motion was 5-90° of flexion.

**Figure 9** AP (A) and lateral (B) radiographs show a comminuted impaction fracture of the volar middle phalangeal base with dorsal subluxation. Volar (C) and lateral (D) intraoperative photographs were taken after the application of the fixator. AP (E) and lateral (F) radiographs taken 3 days postoperatively confirmed maintenance of reduction. Clinical photographs were taken of maximum active flexion (G) and maximum active extension (H) at 4-months follow-up, and AP (I) and lateral (J) radiographs showed a healed fracture and congruent joint.





**Figure 10** AP (A) and lateral (B) radiographs showed a middle phalangeal pilon fracture of the index finger with extreme articular displacement. An intraoperative photograph (C) was taken after the application of external fixator. Final AP (D) and lateral (E) fluoroscopic images were taken in the operating room after the application of the fixator. AP (F) and lateral (G) radiographs obtained 5 months after the initial injury showed a healed fracture and mostly concentric joint. Clinical photographs 9 months after the injury show good flexion (H) and extension (I) of the index PIP.



## Conclusions

Dynamic external fixation of digits as described in this article is a useful technique to treat unstable PIP fracture-dislocations. It reliably results in a healed fracture and maintenance of a concentric reduction, and it is an inexpensive device that can be easily applied. Though it may not prevent intra-articular step-offs and subsequent arthritis in all cases, the dynamic fixator results in satisfactory treatment of pain and preservation of function for complex and challenging fractures.

## References

- McElfresh EC, Dobyns JH, O'Brien ET: Management of fracture-dislocation of the proximal interphalangeal joints by extension-block splinting. *J Bone Joint Surg Am* 54:1705-1711, 1972
- Viegas SF: Extension block pinning for proximal interphalangeal joint fracture dislocations: Preliminary report of a new technique. *J Hand Surg Am* 17:896-901, 1992
- Aladin A, Davis TR: Dorsal fracture-dislocation of the proximal interphalangeal joint: A comparative study of percutaneous Kirschner wire fixation versus open reduction and internal fixation. *J Hand Surg Br* 30:120-128, 2005
- Wolfe SW, Katz LD: Intra-articular impaction fractures of the phalanges. *J Hand Surg Am* 20:327-333, 1995
- Williams RM, Kiefhaber TR, Sommerkamp TG, et al: Treatment of unstable dorsal proximal interphalangeal fracture/dislocations using a hemi-hamate autograft. *J Hand Surg Am* 28:856-865, 2003
- Williams RM, Hastings H 2nd, Kiefhaber TR: PIP fracture/dislocation treatment technique: Use of a hemi-hamate resurfacing arthroplasty. *Tech Hand Up Extrem Surg* 6:185-192, 2002
- Eaton RG, Malerich MM: Volar plate arthroplasty of the proximal interphalangeal joint: A review of ten years' experience. *J Hand Surg Am* 5:260-268, 1980
- Agee JM: Unstable fracture dislocations of the proximal interphalangeal joint of the fingers: A preliminary report of a new treatment technique. *J Hand Surg Am* 3:386-389, 1978
- Slade JF: A Dynamic Distraction External Fixation Device for the Proximal Interphalangeal Joint, Annual Meeting of the American Society for Plastic and Reconstructive Surgery, Boston, 1990
- Slade JF, Baxamusa T, Wolfe SW: External fixation of proximal interphalangeal joint fracture dislocations. *Atlas Hand Clin* 5:1-29, 2000
- Robertson RC, Cawley JJ Jr, Faris AM: Treatment of fracture-dislocation of the interphalangeal joints of the hand. *J Bone Joint Surg Am* 28:68-70, 1946
- Agee JM: Unstable fracture dislocations of the proximal interphalangeal joint. Treatment with the force couple splint. *Clin Orthop Relat Res* 214:101-112, 1987
- Inanami H, Ninomiya S, Okutsu I, et al: Dynamic external finger fixator for fracture dislocation of the proximal interphalangeal joint. *J Hand Surg Am* 18:160-164, 1993
- Johnson D, Tiernan E, Richards AM, et al: Dynamic external fixation for complex intra-articular phalangeal fractures. *J Hand Surg Br* 29:76-81, 2004
- Allison DM: Results in the treatment of fractures around the proximal interphalangeal joint with a pin and rubber traction system. *J Hand Surg Br* 23:700-701, 1998
- Badia A, Riano F, Ravikoff J, et al: Dynamic intradigital external fixation for proximal interphalangeal joint fracture dislocations. *J Hand Surg Am* 30:154-160, 2005
- Bain GI, Mehta JA, Heptinstall RJ, et al: Dynamic external fixation for injuries of the proximal interphalangeal joint. *J Bone Joint Surg Br* 80:1014-1019, 1998
- De Smet L, Fabry G: Treatment of fracture-dislocations of the proximal interphalangeal joint with the "pins & rubbers" traction system. *Acta Orthop Belg* 64:229-232, 1998
- Deshmukh SC, Kumar D, Mathur K, et al: Complex fracture-dislocation of the proximal interphalangeal joint of the hand. Results of a modified pins and rubbers traction system. *J Bone Joint Surg Br* 86:406-412, 2004
- Fahmy NR, Kenny N, Kehoe N: Chronic fracture dislocations of the proximal interphalangeal joint. Treatment by the "S" Quattro. *J Hand Surg Br* 19:783-787, 1994
- Gaul JS Jr, Rosenberg SN: Fracture-dislocation of the middle phalanx at the proximal interphalangeal joint: Repair with a simple intradigital traction-fixation device. *Am J Orthop (Belle Mead NJ)* 27:682-688, 1998
- Krakauer JD, Stern PJ: Hinged device for fractures involving the proximal interphalangeal joint. *Clin Orthop Relat Res* 327:29-37, 1996
- Morgan JP, Gordon DA, Klug MS, et al: Dynamic digital traction for unstable comminuted intra-articular fracture-dislocations of the proximal interphalangeal joint. *J Hand Surg Am* 20:565-573, 1995
- Skoff HD: A proximal interphalangeal joint fracture-dislocation treated by limited open (percutaneous) reduction and dynamic external fixation. *Plast Reconstr Surg* 99:587-589, 1997
- Stark RH: Treatment of difficult PIP joint fractures with a mini-external fixation device. *Orthop Rev* 22:609-615, 1993
- Suzuki Y, Matsunaga T, Sato S, et al: The pins and rubbers traction system for treatment of comminuted intraarticular fractures and fracture-dislocations in the hand. *J Hand Surg Br* 19:98-107, 1994
- Kiefhaber TR, Stern PJ: Fracture dislocations of the proximal interphalangeal joint. *J Hand Surg Am* 23:368-380, 1998
- Stern PJ, Roman RJ, Kiefhaber TR, et al: Pilon fractures of the proximal interphalangeal joint. *J Hand Surg Am* 16:844-850, 1991
- Ruland RT, Hogan CJ, Cannon DL, et al: Use of dynamic distraction external fixation for unstable fracture-dislocations of the proximal interphalangeal joint. *J Hand Surg Am* 33:19-25, 2008
- Ellis SJ, Cheng R, Prokops P, et al: Treatment of proximal interphalangeal dorsal fracture-dislocation injuries with dynamic external fixation: A pins and rubber band system. *J Hand Surg Am* 32:1242-1250, 2007
- Merrell G, Slade JF: Dislocations and ligament injuries in the digits, in Wolfe SW, Hotchkiss RN, Pederson WC, et al (eds): *Green's Operative Hand Surgery* 6th ed. Philadelphia, PA: Elsevier, 2011, pp 300-303
- De Smet L, Boone P: Treatment of fracture-dislocation of the proximal interphalangeal joint using the Suzuki external fixator. *J Orthop Trauma* 16:668-671, 2002
- Gutow A, Slade JF: A dynamic distraction fixator for proximal interphalangeal joint fractures: Indications for use, technique of application, and case studies. *Orthop Trans* 20:207, 1996