

# Planning Brachial Plexus Surgery: Treatment Options and Priorities

Robert H. Brophy, MD<sup>a</sup>, Scott W. Wolfe, MD<sup>a,b,\*</sup>

<sup>a</sup>Hospital for Special Surgery, 535 East 70th Street, New York, NY 10021, USA

<sup>b</sup>Cornell-Weill Medical Center, 525 East 68th Street, New York, NY 10021, USA

Brachial plexus injuries are devastating and strike a predominantly young, active population. These injuries are most often caused by high-energy motorcycle and motor vehicle accidents. Although such injuries have plagued mankind for centuries, as evidenced by their description in the *Iliad*, little progress had been made in their management and treatment until the last few decades. Advances in basic science and anatomy during and following World War II set the stage for breakthrough progress in surgical techniques starting in the 1960s. This progress has led to increasingly successful clinical intervention for these otherwise catastrophic injuries. A crucial aspect of improving outcomes has been careful preparation for surgery, including accurate classification of the injury, appropriate timing of the intervention, and precise preoperative planning.

## Injury classification

Brachial plexus injuries can be divided into two broad categories: supraclavicular injuries and infraclavicular injuries (Fig. 1). Supraclavicular injuries are more common and represent 70% to 75% of traumatic brachial plexus injuries. These injuries result most often from a traction mechanism, and patients are unlikely to recover without surgery. Half of supraclavicular injuries involve all five spinal levels (C5–T1) [1]. Of these complete five-level injuries, most (60%) are upper trunk (C5–C6/7) rupture in combination with lower

trunk (C7/8–T1) avulsion. Approximately 30% of these injuries are true complete five-level avulsion injuries, and the remaining 10% are actually C4 through T1 complete avulsion injuries with a very poor prognosis.

The most common pattern of incomplete supraclavicular injury is an upper trunk palsy. These types of injuries represent approximately 35% of all supraclavicular injuries and are typically characterized by avulsion or proximal rupture of C5/C6, with or without an injury of C7. The lower trunk is characteristically spared, or recovers relatively quickly from a transient neuropraxia. The avulsion of C6–C8, with sparing or recovery of C5 and T1, occurs much less frequently and represents 8% of all supraclavicular injuries. Isolated C8 and T1 avulsion or trunk rupture is rare, occurring in only 3% of all supraclavicular injuries. It is important to remember that 15% of supraclavicular injuries have concomitant segmental injuries at or below the clavicle where the peripheral nerves branch from the plexus [2]. The musculocutaneous, axillary, and suprascapular nerves are particularly vulnerable to traction injury because of soft tissue tethers near their origins. In addition, a prefixed (C4 contribution to the upper trunk) or postfixed (T2 contribution to the lower trunk) plexus may confuse the presentation of a supraclavicular injury.

Infraclavicular injuries constitute 25% to 33% of brachial plexus injuries [1–3]. These injuries tend to occur at the level of the cords or peripheral nerves and are usually incomplete. They are often caused by shoulder fractures or dislocations. Almost half (45%) are considered whole limb injuries and are frequently associated with shoulder trauma, including fracture-dislocation,

---

\* Corresponding author. Hospital for Special Surgery, 535 East 70th Street, New York, NY 10021.

E-mail address: wolfes@hss.edu (S.W. Wolfe).

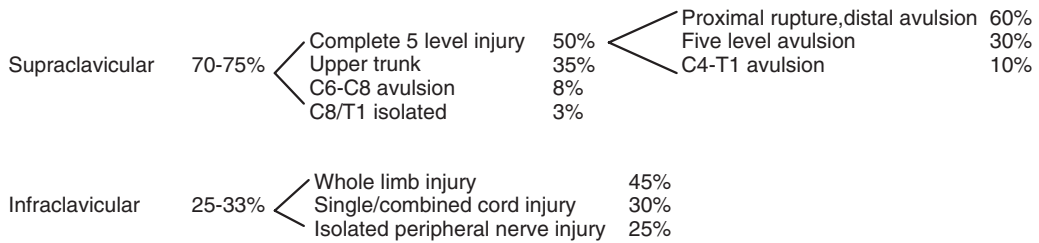


Fig. 1. Distribution of location and type of brachial plexus injuries.

scapulothoracic dissociation, or clavicular fractures. Approximately 30% are single or combined cord injuries. Isolated peripheral nerve palsies of the axillary, radial, or musculocutaneous nerve make up the remaining 25% of infraclavicular injuries. It is important to remember that 5% to 25% of infraclavicular injuries are associated with concomitant rupture or thrombosis of the axillary artery [1–3].

Brachial plexus injuries caused by penetrating trauma usually occur in the infraclavicular plexus, although any combination of injury to different levels of the plexus can be seen. Gunshot wounds (GSWs) usually cause neuropraxic injury to the plexus. Iatrogenic injuries can be seen related to various procedures. For example, resection of the first rib can be associated with injury at the division or cord level. Axillary lymph node dissection may endanger the long thoracic or thoracodorsal nerves, and cervical lymph node biopsy is frequently complicated by injury to the spinal accessory nerve. Shoulder procedures, especially stabilization or capsular release, may occasionally be associated with injuries of the axillary, median, or radial nerves.

Spontaneous recovery within 1 year is more likely in infraclavicular injuries than in supraclavicular injuries. It has been suggested that these injuries are more likely to recover because they occur farther from the nerve's "anchorage" point [3], and are thus less likely to involve nerve disruption. Surgery is generally not necessary in closed cord injuries below the clavicle. It is important to remember, however, that the axillary nerve is tethered at the quadrangular space and thus more vulnerable to axonal injury. Isolated axillary nerve injuries have a less favorable recovery rate and may require surgical intervention, including exploration and possibly excision and grafting. Similarly, the musculocutaneous nerve is tethered where it enters the coracobrachialis, and the suprascapular nerve is tethered at the suprascapular notch.

### Timing of surgical intervention

Perhaps the most crucial aspect of planning surgical intervention for brachial plexus injury is selecting the timing of surgery.

Indications for acute exploration include the following: concomitant vascular injury, open injuries caused by sharp laceration, and crush or contaminated open wounds. With crush or contaminated wounds, it is advisable to identify and tag divided nerve stumps for later repair. Devitalized tissue should be debrided and bony injuries stabilized, and any accompanying arterial injuries should be repaired primarily. Early exploration, within 1 to 2 weeks, is recommended for unequivocal, complete C5-T1 avulsion injuries [4]. Plexus injuries that occur from a low-energy GSW are generally neuropraxic and should not be routinely explored.

Delayed exploration (3 mo after the initial injury) is recommended for complete injuries with no recovery by clinical examination or electromyography (EMG) at 12 weeks post injury. Other candidates for exploration are those who show distal recovery without regaining clinical or electrical evidence of proximal muscle function. Patients with iatrogenic injury, as may occur following neck exploration or lymph node biopsy, should also be explored relatively early, particularly if electrodiagnostic testing shows complete denervation without evidence of recovering motor unit potentials.

Nerve reconstruction is not routinely recommended in adults more than 9 months after the inciting injury [5–10], although reconstruction has been attempted in patients up to 12 months later [11], and some authors have reported results of patients treated more than 12 months after their initial trauma [9,12,13]. One study found a statistically significant difference in the average time from injury to surgery between patients with successful outcomes, treated, on average, 4.3 months after

their initial accident, when compared with patients with unsuccessful outcomes, treated at an average of 6.3 months after injury ( $P = 0.003$ ) [5]. Another study showed significantly better biceps strength in patients treated within 6 months of their injury compared with patients treated more than 12 months after their injury ( $P < 0.05$ ) [9].

Age is an important variable to consider with regards to timing of brachial plexus surgery. Some authors have suggested that an age of more than 50 years is a contraindication for surgical exploration [13]. Other authors have reported encouraging results with older patients [11,12]. One study, which reported on 63 patients with a mean age of 23 years and an age range of 10 to 52 years, found no statistically significant relationship between clinical outcome and the age of the patient [5]. As a general rule, most surgeons are more likely to operate on younger patients, and younger patients tend to do better than older patients. Thus, younger patients tend to be offered more aggressive surgical options even later after the initial injury than older patients.

## Preoperative planning

### *Physical examination*

Once the decision has been made to operate, careful preoperative planning with the entire surgical team is essential (Box 1). Clinical records should be examined with special attention to the patient's postinjury physical examination and subsequent recovery, if any. Careful and repeated evaluation of upper extremity motor and sensory function is mandatory.

When evaluating supraclavicular lesions, it is important to differentiate between avulsion and extraforaminal injuries. Although abrasions and

ecchymosis in the posterior triangle of the neck are commonly seen in both types of injury, a positive Tinel's sign suggests extraforaminal injury. Root avulsion or preganglionic injury is suggested by numerous findings, including an elevated hemidiaphragm and lost sensation above the clavicle. Horner's syndrome suggests an avulsion injury to the lower two roots. Fractures of the C7 transverse process or the first rib are also associated with preganglionic injury to the lower two roots. The head may tilt away from the injured side, which indicates complete five-level intradural injury. The presence of unremitting deafferentation pain, described by patients as burning or crushing in character, also supports a diagnosis of preganglionic injury. Paradoxically, peripheral sympathetic tone may be preserved, because the sympathetic cell bodies reside in the sympathetic trunk, outside of the cord and distal to the zone of injury.

Different physical examination findings are associated with infraclavicular injuries. There may be sparing of peripheral nerves originating from the cords—for example, the subscapularis nerves (upper, middle, lower) and the pectoral nerves (medial, lateral). Patients may have decreased or absent peripheral sympathetic tone. A strongly positive Tinel's sign is almost always present in an infraclavicular lesion.

### *Electrodiagnostic studies*

Electrodiagnostic studies should be reviewed in detail to document the level and extent of injury. Somatosensory evoked potentials (SEPs) and sensory nerve action potentials have been used to help determine the location of brachial plexus lesions [14,15]. EMG can be used to assess the peripheral and paraspinal musculature. Denerated rhomboids, serratus anterior, and trapezius all suggest avulsion of the C5-7 roots. A repeat EMG at least 6 weeks after an initial EMG is helpful to look for spontaneous recovery. Intact proximal musculature or recovery in proximal musculature suggests intact rootlets, as does the presence of at least some distal motor function. Sensory nerve conduction studies can be helpful, because preserved sensory conduction in the presence of anesthesia strongly supports a preganglionic supraclavicular injury.

### *Imaging studies*

All imaging studies should be reviewed, with an emphasis on differentiating between pre- and

#### **Box 1. Preoperative planning priorities for brachial plexus injury surgery**

1. Review clinical examinations
2. Scrutinize electrodiagnostic studies
3. Review CT myelography/imaging
4. Assemble operative team, plan for intraoperative electrodiagnostic studies
5. Plan a preoperative conference, including priorities and contingency plans
6. Prepare patient's expectations

postganglionic injuries. Myelography, CT myelography, and MRI are particularly helpful for this purpose. No imaging modality has been shown to be clearly superior, especially if used alone, although given a choice of only one modality, most brachial plexus surgeons would probably select CT myelography (Fig. 2). Nagano et al [16] showed an association between progressive myelographic abnormalities and preganglionic injury, with 90% of normal-appearing roots found to be postganglionic injury, whereas a traumatic meningocele was associated with preganglionic injury 98% of the time. Intermediate findings were associated with lesser rates of accuracy. CT myelography has been shown to have accuracy ranging from 70% to 95% [12,17–20]. Assessing the C8 and T1 roots is more difficult with CT myelography, because of the increasing obliquity of the more caudal spinal nerves and signal artifact arising in short, stout necks [21]. Using myelography in combination with CT myelography is likely to be more accurate. MRI is considered less accurate than CT myelography for detecting nerve root avulsion [12,21,22], although MRI is noninvasive and visualizes the extraforaminal plexus [23]. Hems et al [24] reported that a normal MRI of the supraclavicular plexus excludes significant postganglionic injury. Research continues into improving techniques for MRI imaging of brachial plexus lesions [21,25].

#### *Logistics and prioritization*

While reviewing the diagnostic data, the operative team needs to be organized, including making arrangements for intraoperative

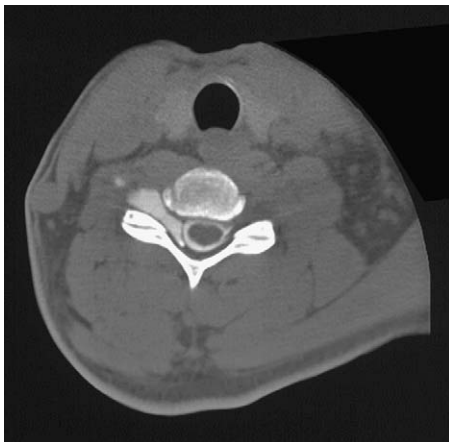

Fig. 2. CT myelogram of nerve root avulsion.

electrodiagnostic testing. A preoperative conference is helpful for assigning intraoperative priorities, developing an operative plan, and preparing contingency plans for possible intraoperative complications.

Prioritization is essential. First, it is important to clearly understand the anatomy of the injured plexus in each patient. It is equally important to identify what is available for possible nerve transfer. The surgeon must ask what is realistic to expect for a given patient, because it is important to set the patient's goals for any operation in line with the surgical expectations.

For functional priorities, it is generally agreed that elbow flexion is the most important function to restore. Active shoulder control is considered next most important, with abduction, external rotation, and scapular stabilization prioritized in that order. Long thoracic nerve reinnervation should be performed whenever possible. Proximal radial nerve motor function can often be restored, with triceps function more likely to return than wrist and finger extension. Restoring useful ulnar and median nerve motor function is not a consistently realistic goal for surgical intervention, although experimental efforts are focusing on this area. Sensation in the median nerve distribution should be restored if at all possible, and this factor has been shown to relieve pain in multilevel avulsion injuries, even in the absence of functional median nerve motor recovery. Berman et al [26] described late (>1 y post injury) intercostal nerve transfer for the sole purpose of pain relief in patients with brachial plexus injury. Significant relief was noted in 16 of 19 patients an average of 8 months after transfer.

#### *Surgical options*

Once the priorities for returning function have been assigned, the options for restoring function need to be explored. The authors focus on surgical options for restoring the function of the brachial plexus, including neurolysis, nerve repair, nerve grafting, and nerve transfer.

Neurolysis can be done, but it is rarely able to restore function as an isolated intervention. Narakas [27] found that neurolysis was effective only if scar tissue was observed around the nerve or inside the epineurium, preventing recovery or causing pain. Pre- and postneurolysis direct nerve stimulation is mandatory to evaluate improvement in nerve conduction. Clinically, it is often difficult to assess the efficacy of neurolysis because

improvement may also be from spontaneous recovery.

Nerve repair is not a viable option in most subacute or delayed cases and should be considered only in sharp transections with excellent fascicular pattern and minimal scar. Tension on the repair is detrimental to recovery and should be avoided.

Nerve graft is indicated for well-defined ruptured nerve ends without segmental injury. Intraoperatively, a good fascicular pattern should be seen after the neuroma is excised. A portion of the resected nerve can be sent to pathology for intraoperative evaluation of the degree of scarring and the viability of the remaining fascicles. SEPs should show conductivity of stimulated roots [14,15,28,29]. Possible sources for nerve graft include the sural, antebrachial cutaneous, radial sensory, and possibly the ulnar nerve. The sural nerve can provide up to 40 cm of cable material. The donor nerve should be left in situ until the recipient bed is prepared. Before implantation, the graft orientation should be reversed to minimize axonal branch loss. Generally, shorter grafts (<10 cm) result in more successful outcomes than longer grafts [5,9,30,31], although one study found no relationship between graft length ( $\leq 25$  cm) and graft success [32] when restoring function to the deltoid and biceps. Nerve grafting for distal function has been less successful compared with grafts to restore proximal function [32]. Vascularized nerve grafts have not been shown to achieve superior results compared with free-nerve grafts [33]. Surgical technique is considered the most important factor influencing results of nerve grafts [9], with the goal of perfect coaptation with no tension at the nerve union site.

Nerve transfer, or neurotization, options include intraplexal and extraplexal sources. Plexoplexal options include the undamaged roots, which often have to be confirmed intraoperatively with electrodiagnostic testing. Other options include the medial pectoral nerve and medial cord/ulnar nerve. Oberlin et al [34] described the anastomosis of one or two fascicles of the ulnar nerve to the biceps. Extraplexal options include the spinal accessory nerve and intercostal nerves. The phrenic nerve is also an option, and the motor branches of the deep cervical plexus (C3-4) can be used as donors as well. With the exception of the deep cervical plexus, all of these options have been shown in one or more reports to restore M3 or better elbow flexion in nearly two thirds of patients [11-13].

A plan to use undamaged roots requires contingency planning in the event of unexpected findings on intraoperative electrodiagnostic studies. The Oberlin technique is indicated for patients with upper trunk avulsion and no lower trunk injury [13], and the use of one or two fascicles of the ulnar nerve has not been reported to show a significant motor or sensory deficit postoperatively [34-36]. Success rates reported with the Oberlin transfer have been very good, with 94% to 100% of patients achieving M3 or better biceps strength, and 75% to 94% achieving at least M4 biceps strength [34-36]. The procedure requires an intact lower plexus, however. As an alternative, the spinal accessory nerve is a pure motor nerve, but its use is limited to one or two of its distal branches so as to preserve important upper trapezius function. On occasion, high-energy injuries may be associated with disruption of the spinal accessory nerve; this situation is usually evidenced by severe atrophy on physical examination. There is no known deficit associated with intercostal nerve transfer, but these small nerves may be damaged in patients with pneumothorax, chest tube, multiple rib fractures, or concomitant spinal cord injury. The phrenic nerve is attractive as a donor because it is a pure motor nerve with abundant axons, but its use carries the theoretic risk of endangering respiratory function, especially in patients who undergo simultaneous intercostal nerve transfer. A study by Gu et al [37] showed no measurable decrement in pulmonary function after phrenic nerve transfer. Transferring the motor branches of the C3-4 cervical plexus may endanger any remaining scapular stability in patients with five-level avulsion injuries.

Contralateral C7 transfer is another option, and preliminary results have been encouraging [38-40]. The clinical indication is a complete plexopathy with multiple avulsions and limited donor possibilities. The contralateral C7 root can be extended by means of a vascularized ulnar nerve graft in patients with C8-T1 avulsions, and the median nerve is the most frequent recipient. Donor deficits have been reported, including biceps and triceps motor and C7 sensory function, although the risk is currently not considered significant [39,41,42].

Another option is transferring the nerve to the long head of the triceps to the anterior branch of the axillary nerve to restore deltoid motor function, as described by Witoonchart et al [43] and Leechevongvongs et al [44]. This transfer has been shown to be anatomically feasible [43] and



clinically promising when used in conjunction with spinal accessory nerve transfer to the supra-scapular nerve [44].

Once the potential nerve transfer donors have been identified, the surgeon must match these with realistic targets for reinnervation. The spinal accessory nerve can be repaired to the supra-scapular nerve or to the musculocutaneous nerve. The phrenic nerve or an undamaged C5 root can be used to reinnervate the axillary nerve. Intercostals can be used for various combinations of the musculocutaneous, long thoracic, radial, or median nerves. Contralateral C7 transfer is usually for the median nerve. The nerve to the long head of the triceps is transferred to the anterior branch of the axillary nerve.

One important factor for these nerve transfers is the number of axons available in possible donors [45]. The number of myelinated nerve axons in a single branch to the pectoral muscle is roughly 400 to 600, whereas the phrenic nerve contains 800 of these axons. One intercostal nerve contains 1300 myelinated axons, the long thoracic nerve 1600, and the spinal accessory nerve 1700 myelinated axons. The motor branches of the deep cervical plexus contain 3400 to 4000 myelinated axons, and C7 may hold between 16,000 and 40,000 mixed motor and sensory axons. The nerve to the long head of the triceps contains an average of roughly 1200 axon fibers [43]. In comparison, a typical recipient, such as the musculocutaneous nerve, is composed of approximately 6000 motor axons [9]. The anterior branch of the axillary nerve has been shown to contain an average of 2700 axons [43].

#### *Patient expectations*

Managing patient expectations is perhaps the most important part of preoperative planning and preparation. Patients need to understand the limits of the best possible outcome and the possibility that no or limited functional improvement may occur after surgery. Prognosis is highly dependent on the pattern of injury. Complete C4 to T1 injuries are considered the most severe and are virtually irreparable, but these injuries are uncommon. Avulsion injuries from C5 to T1 have been shown to be amenable to restoration of shoulder and elbow function, but distal function is virtually impossible to restore with current techniques. Proximal root rupture with distal root avulsion also allows for recovery of shoulder and elbow function, and patients may recover some

sensation and get relief of pain. The ideal candidates for surgery are patients with proximal rupture or avulsion and sparing of the lower trunk. These patients retain hand function and often get good shoulder and elbow function. Infraclavicular lesions are amenable to direct repair and may require nerve grafting for segmental defects. Nerve transfers are usually not necessary.

#### **Summary**

Brachial plexus injuries are devastating and usually result from high-energy trauma in young patients. Clinicians treating brachial plexus injuries need to recognize the pattern of injury presenting in each patient. Most injuries can be described as either supraclavicular or infraclavicular. The specific injury is determined by means of a precise workup, including careful physical examination, electrodiagnostic studies, and imaging studies; a thorough workup is essential for successful preoperative planning. Priorities need to be identified and matched with available resources in each patient. A growing number of good treatment alternatives are available. Finally, counseling patients toward realistic expectations is a critical component of preparation for surgery.

#### **References**

- [1] Birch R. Brachial plexus injuries. *J Bone Joint Surg Br* 1995;78(6):986–92.
- [2] Alnot JY. Traumatic brachial plexus palsy in the adult: retro- and infraclavicular lesions. *Clin Orthop* 1988;237:9–16.
- [3] Leffert RD, Seddon H. Infraclavicular brachial plexus injuries. *J Bone Joint Surg Br* 1965;47(1):9–22.
- [4] Megalon G, Bordeaux J, Legre R, Aubert JP. Emergency versus delayed repair of severe brachial plexus injuries. *Clin Orthop* 1988;237:32–5.
- [5] Bentolila V, Nizard R, Bizot P, Sedel L. Complete traumatic brachial plexus palsy. Treatment and outcome after repair. *J Bone Joint Surg Am* 1999;81(1):20–8.
- [6] Millesi H. Brachial plexus injuries. Nerve grafting. *Clin Orthop* 1988;237:36–42.
- [7] Millesi H. Interfascicular grafts for repair of peripheral nerves of the upper extremity. *Orthop Clin North Am* 1977;8(2):387–404.
- [8] Nagano A, Tsuyama N, Ochiai N, Hara T, Takahashi M. Direct nerve crossing with the intercostal nerve to treat avulsion injuries of the brachial plexus. *J Hand Surg Am* 1989;14(6):980–5.
- [9] Samii M, Carvalho GA, Nikkhah G, Penkert G. Surgical reconstruction of the musculocutaneous

- nerve in traumatic brachial plexus injuries. *J Neurosurg* 1997;87(6):881–6.
- [10] Songcharoen P, Mahaisavariya T, Chotigavanich C. Spinal accessory neurotization for restoration of elbow flexion in avulsion injuries of the brachial plexus. *J Hand Surg Am* 1996;21(3):387–90.
- [11] Merrell GA, Barrie KA, Katz DL, Wolfe SW. Results of nerve transfer techniques for restoration of shoulder and elbow function in the context of a meta-analysis of the English literature. *J Hand Surg Am* 2001;26(2):303–14.
- [12] Dubuisson AS, Kline DG. Brachial plexus injury: a survey of 100 consecutive cases from a single service. *Neurosurgery* 2002;51(3):673–83.
- [13] Nagano A. Treatment of brachial plexus injury. *J Orthop Sci* 1998;3(1):71–80.
- [14] Jones SJ, Parry CB, Landi A. Diagnosis of brachial plexus traction lesions by sensory nerve action potentials and somatosensory evoked potentials. *Injury* 1981;12(5):376–82.
- [15] Synek VM, Cowan JC. Somatosensory evoked potentials in patients with supraclavicular brachial plexus injuries. *Neurology* 1982;32(12):1347–52.
- [16] Nagano A, Ochiai N, Sugioka H, Hara T. Usefulness of myelography in brachial plexus injuries. *J Hand Surg Br* 1989;14:59–64.
- [17] Carvalho GA, Nikkhhah G, Matthies G, Penkert G, Samii M. Diagnosis of root avulsions in traumatic brachial plexus injuries: value of computerized tomography myelography and magnetic resonance imaging. *J Neurosurg* 1997;86(1):69–76.
- [18] Marshall RW, De Silva RDD. Computerised axial tomography in traction injuries of the brachial plexus. *J Bone Joint Surg Br* 1986;68(5):734–8.
- [19] Oberle J, Antoniadis G, Rath SA, et al. Radiological investigations and intra-operative evoked potentials for the diagnosis of nerve root avulsion: evaluation of both modalities by intradural root inspection. *Acta Neurochir* 1998;140(6):527–31.
- [20] Walker AT, Chaloupka JC, de De Lotbiniere ACJ, Wolfe SW, Goldman R, Kier EL. Detection of nerve rootlet avulsion on CT myelography in patients with birth palsy and brachial plexus injury after trauma. *AJR Am J Roentgenol* 1996;167(5):1283–7.
- [21] Tavakkolizadeh A, Saifuddin A, Birch R. Imaging of adult brachial plexus traction injuries. *J Hand Surg Br* 2001;26(3):183–91.
- [22] van Es HW. MRI of the brachial plexus. *Eur Radiol* 2001;11(2):325–36.
- [23] Gupta RK, Mehta VS, Banerji AK, Jain RK. MR evaluation of brachial plexus injuries. *Neuroradiology* 1989;31(5):377–81.
- [24] Hems TE, Birch R, Carlstedt T. The role of MRI in the management of traction injuries of the adult brachial plexus. *J Hand Surg Br* 1999;24(5):550–5.
- [25] Doi K, Otsuka K, Okamoto Y, Fujii H, Hattori Y, Baliarsing AS. Cervical root avulsion in brachial plexus injuries: magnetic resonance imaging classification and comparison with myelography and computerized tomography myelography. *J Neurosurg* 2002;96(3 Suppl):277–84.
- [26] Berman J, Anand P, Chen L, Taggart M, Birch R. Pain relief from preganglionic injury to the brachial plexus by late intercostal nerve transfer. *J Bone Joint Surg Br* 1996;78(5):759–60.
- [27] Narakas A. Brachial plexus surgery. *Orthop Clin North Am* 1981;12(2):303–23.
- [28] Turkof E, Millesi H, Turkof R, Pfundner P, Mayr N. Intraoperative electrodiagnostics (transcranial electrical motor evoked potentials) to evaluate the functional status of anterior spinal roots and spinal nerves during brachial plexus surgery. *Plast Reconstr Surg* 1997;99(6):1632–41.
- [29] Turkof E, Monsivais J, Dechtyar I, Bellolo H, Millesi H, Mayr N. Motor evoked potential as a reliable method to verify the conductivity of anterior spinal roots in brachial plexus surgery: an experimental study on goats. *J Reconstr Microsurg* 1995;11(5):357–62.
- [30] Chuang DC, Epstein MD, Yeh MC, Wei FC. Functional restoration of elbow flexion in brachial plexus injuries: results in 167 patients (excluding obstetric brachial plexus injury). *J Hand Surg Am* 1993;18(2):285–91.
- [31] Hentz VR, Narakas A. The results of microneurosurgical reconstruction in complete brachial plexus palsy: assessing outcome and predicting results. *Orthop Clin North Am* 1988;19(1):107–14.
- [32] Ochiai N, Nagano A, Sugioka H, Hara T. Nerve grafting in brachial plexus injuries. Results of free grafts in 90 patients. *J Bone Joint Surg Br* 1996;78(5):754–8.
- [33] Birch R, Dunkerton M, Bonney G, Jamieson AM. Experience with the free vascularised ulnar nerve graft in repair of supraclavicular lesions of the brachial plexus. *Clin Orthop* 1988;237:96–104.
- [34] Oberlin C, Beal D, Leechavengvongs S, Salon A, Dauge MC, Sarcy JJ. Nerve transfer to biceps muscle using a part of ulnar nerve for C5-C6 avulsion of the brachial plexus: anatomical study and report of four cases. *J Hand Surg Am* 1994;19(2):232–7.
- [35] Leechavengvongs S, Witoonchart K, Uerpairojkit C, Thuvasethakul P, Ketmalasiri W. Nerve transfer to biceps muscle using a part of the ulnar nerve in brachial plexus injury (upper arm type): a report of 32 cases. *J Hand Surg Am* 1998;23(4):711–6.
- [36] Sungpet A, Suphachatwong C, Kawinwonggowit V, Patradul A. Transfer of a single fascicle from the ulnar nerve to the biceps muscle after avulsions of upper roots of the brachial plexus. *J Hand Surg Br* 2000;25(4):325–8.
- [37] Gu YD, Wu MM, Zhen YL, et al. Phrenic nerve transfer for brachial plexus motor neurotization. *Microsurgery* 1989;10(4):287–9.

- [38] Gu Y, Xu J, Chen L, Wang H, Hu S. Long term outcome of contralateral C7 transfer: a report of 32 cases. *Chin Med J* 2002;115(6):866–8.
- [39] Songcharoen P, Wongtrakul S, Mahaisavariya B, Spinner RJ. Hemicontralateral C7 transfer to median nerve in the treatment of root avulsion brachial plexus injury. *J Hand Surg Am* 2001;26(6):1058–64.
- [40] Waikakul S, Orapin A, Vanadurongwan V. Clinical results of contralateral C7 root neurotization to the median nerve in brachial plexus injuries with total root avulsions. *J Hand Surg Br* 1999;24(5):556–60.
- [41] Chuang DC, Cheng SL, Wei FC, Wu CL, Ho YS. Clinical evaluation of C7 spinal nerve transection: 21 patients with at least 2 years' follow-up. *Br J Plast Surg* 1998;51(4):285–90.
- [42] Gu YD, Chen DS, Zhang GM, et al. Long-term functional results of contralateral C7 transfer. *J Reconstr Microsurg* 1998;14(1):57–9.
- [43] Witoonchart K, Leechavengvongs S, Uerpaiojkit C, Thuvasethakul P, Wongnopsuwan V. Nerve transfer to deltoid muscle using the nerve to the long head of the triceps, part I: an anatomic feasibility study. *J Hand Surg Am* 2003;28(4):628–32.
- [44] Leechavengvongs S, Witoonchart K, Uerpaiojkit C, Thuvasethakul P. Nerve transfer to deltoid muscle using the nerve to the long head of the triceps, part II: a report of 7 cases. *J Hand Surg Am* 2003;28(4):633–8.
- [45] Chuang DC. Neurotization procedures for brachial plexus injuries. *Hand Clin* 1995;11(4):633–45.