

# Distal Radial Fracture Management With an Intramedullary Cage and Fragment Fixation

Michael K. Strassmair, MD,\* Michael Jonas, MD,† Walter Schäfer, MD,‡ Andrew Palmer, MD§

**Purpose** To examine the outcomes associated with the treatment of distal radial fractures with an expandable intramedullary cage and fragment-specific screw fixation.

**Methods** A prospective multicenter case series of 100 patients with a fracture of the distal radius treated with the “Cage System” was undertaken. Primary patient outcomes included Disabilities of the Arm, Shoulder, and Hand, Patient-Related Wrist/Hand Evaluation questionnaires, and adverse events associated with the device. Secondary outcomes included wrist range of motion and radiographic findings.

**Results** Follow-up was performed at intervals of 2 weeks, 4 to 6 weeks, 12 weeks, and 1 year. Ninety-one patients were available for follow-up at 2 weeks, 87 at 4 to 6 weeks, 73 at 3 months, and 61 at 12 months. The mean Disabilities of the Arm, Shoulder, and Hand score at 3 months was 21; at 12 months, it was 9. The mean total Patient-Reported Wrist/Hand Evaluation score at 3 months was 21; at 12 months, it was 11. There were 5 adverse events (5%)—2 involving radial nerve irritation and 3 involving tendon irritation from screws. Four of these 5 patients underwent surgical intervention, a neurolysis in 1 patient and removal of screws in 3. All patients were free of adverse-event symptoms at 3 months' follow-up. Wrist range of motion improved most rapidly in the first 12 weeks following surgery and continued to improve throughout follow-up. The fracture reduction achieved at surgery was maintained throughout the healing process. There was evidence of callus formation at the fracture as early as 2 weeks after surgery with 100% of fractures healed at 3 months.

**Conclusions** An expandable intramedullary cage with fragment-specific screw fixation provides maintenance of fracture reduction with a low complication rate. (*J Hand Surg Am.* 2016;41(8):833–840. Copyright © 2016 The Authors. Published by Elsevier Inc on behalf of the American Society for Surgery of the Hand. This is an open access article under the CC BY-NC-ND license (<http://creativecommons.org/licenses/by-nc-nd/4.0/>).

**Type of study/level of evidence** Therapeutic IV.

**Key words** Distal radial fracture, intramedullary fracture fixation, cage fixation.

From the \*Klinikum Starnberg, Starnberg; the †St. Josef Krankenhaus, Moers; the ‡Kreiskrankenhaus Gummersbach, Gummersbach, Germany; and the §SUNY Upstate Medical University, Institute for Human Performance, Syracuse, NY.

Received for publication January 4, 2016; accepted in revised form May 16, 2016.

No benefits in any form have been received or will be received related directly or indirectly to the subject of this article.

**Corresponding author:** Andrew Palmer, MD, SUNY Upstate Medical University, Institute for Human Performance—3215, 750 East Adams St., Syracuse, NY 13210; e-mail: [palmerak46@gmail.com](mailto:palmerak46@gmail.com).

0363-5023/16/4108-0005  
<http://dx.doi.org/10.1016/j.jhssa.2016.05.008>

FRACTURES OF THE DISTAL RADIUS ARE one of the most common fractures seen in the upper extremity, especially in the elderly with a reported incidence of 195.2 per 100,000.<sup>1–4</sup> Although approximately 60% of distal radius fractures are managed nonsurgically, an increasing trend toward surgical management has been reported as different and improved methods of internal fixation including dorsal plating, nail plate fixation, fragment specific fixation, and volar locked plating have become available.<sup>5–7</sup> The introduction of volar locked plating

in the early 2000s represented a major innovation in the surgical repair of distal radius fractures.<sup>8</sup> Today, volar locking plates are used to treat the majority of surgically managed distal radial fractures.<sup>8</sup> Most existing procedures are relatively invasive, and hardware-related complications including tendon irritation and/or rupture, hardware failure, neurological injury, loss of reduction, delayed or nonunion, and infection are relatively common to all procedures (16%–27%).<sup>9–13</sup> Therefore, the need still exists for a surgical solution that minimizes soft tissue trauma and hardware-related complications, addresses a broad range of fracture patterns, and promotes rapid return to function. The objective of this study was to assess the functional and radiographic outcomes for a series of patients treated with an expandable metallic implant that is deployed into the medullary canal of the distal radius providing a scaffold to which bone fragments can be stabilized using fragment specific screws.

## MATERIALS AND METHODS

A multicenter nonsequential study was undertaken at multiple health centers in Germany after the study protocol was approved by the Ethics Committee in each participating center. The protocol conformed to the ethical guidelines of the 1975 Declaration of Helsinki. Required exclusion criteria for this study, in accordance with Conformité Européenne marked product labeling, included mental illness, alcoholism, foreign body sensitivity, AO class C3 fractures, and open growth plates.

Participating centers were provided financial compensation by the implant manufacturer for completion of required study follow-up only. No payments were made to physicians or patients.

Follow-up comprising completion of the Disabilities of the Arm, Shoulder, and Hand (DASH) and Patient-Related Wrist/Hand Evaluation (PRWHE) forms, measurement of range of motion, and assessment for adverse events was performed at 2 weeks, 4 to 6 weeks, 12 weeks, and 1 year by the principal investigators (M.S., M.J., and W.S.), subinvestigators, and/or site coordinators. Of the 100 patients initially admitted to the study, 91 patients were available for follow-up at 2 weeks, 87 at 4 to 6 weeks, 73 at 12 weeks, and 61 at 1 year.

Patients were lost to follow-up for a number of reasons including voluntary withdrawal by 26 individuals because they were satisfied with the results from their surgery and they, therefore, requested to not have to return for additional follow-up. Seven patients were lost from 1 site because the principal investigator changed practice location. Six patients, at

multiple sites, were excluded because they missed follow-up appointments.

X-rays were obtained before surgery, immediately after surgery, and at intervals up to 1 year. Follow-up x-rays were available on 63 patients at 12 weeks and 48 patients at 1 year. X-rays were taken in compliance with each site's standard of care, which meant, in many instances, x-rays were not allowed after the fracture was judged to be healed out of concern for unnecessary radiation exposure to the patient. X-rays, when available, were evaluated in final follow-up by a board certified orthopedic hand surgeon (A.P.) in regards to radial inclination, volar tilt, ulnar variance, coronal shift, and evidence of fracture healing. Fracture union was judged to be present if osseous bridging across the fracture site was seen in 2 of 3 views as recommended by Rosental et al.<sup>14</sup>

## Surgical technique

All surgical procedures were performed through a standard radial approach. After a reduction of the fracture was obtained by the surgeon, using either closed or open methods and held in place via longitudinal finger trap traction or axially placed K-wires, the technique and instrumentation unique to the Cage Distal Radius System (Conventus Orthopedics, Maple Grove, MN) was utilized. The technique involves entering the radial aspect of the radius using drill bits through a 2- to 3-cm radial incision that is located approximately 3 cm proximal to the articular surface. This is followed by preparation of the site for the implant with the system's reaming device in the subcortical region of the distal radius. The implant is then deployed into the prepared space of the distal radius just proximal to the fracture. The device is locked in its expanded position and fixed to the radial border of the radius with a small side plate and screws. The final step is the introduction of fragment-specific, cannulated screws through the device, across the fracture and into the far cortex.

Postoperative immobilization varied according to the surgeon's preference and the site's standard of care for distal radial fractures. Fifty-five patients underwent no immobilization, 40 utilized a commercial orthosis for 2 weeks, and in 5 patients, a cast was used for 2 weeks. No patients received formal therapy but were instructed to begin range of motion exercises as tolerated.

## RESULTS

Eighty-nine percent of patients were female with a mean age of 68 years. Ninety-three percent were right-handed, although the right and left wrists were

**TABLE 1. Demographic Data**

Characteristic	Subjects
Age (y)	n = 100
Mean	68 ± 12
Range	33–94
Gender	
Female	89% (89 of 100)
Mechanism of injury	n = 100
Fall	96% (96 of 100)
Sports	2% (2 of 100)
Other (MVA)	2% (2 of 100)
AO classification	
A2	27% (27 of 101)
A3	37% (38 of 101)
B1	6% (6 of 101)
B2	5% (5 of 101)
B3	1% (1 of 101)
C1	19% (19 of 101)
C2	5% (5 of 101)
Fractured hand	
Right	51% (51 of 100)
Left	49% (49 of 100)
Dominant hand	
Right	93% (93 of 100)
Left	6% (6 of 100)

MVA, motor vehicle accident.

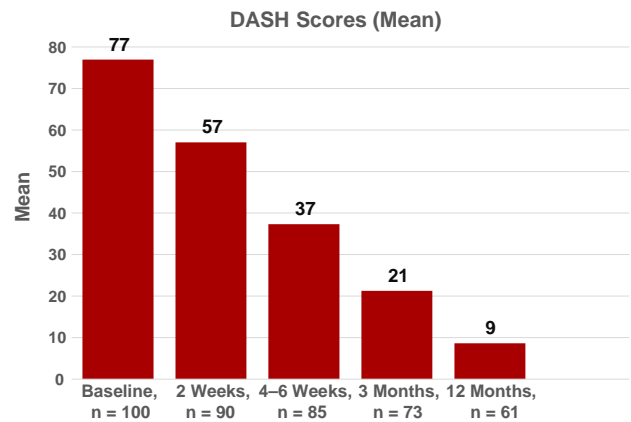
fractured nearly equally. The AO classification of fractures seen included A2, A3, B1, B2, B3, C1, and C2 (Table 1).

### Clinical outcomes

The DASH questionnaire was completed by all patients at the time of injury with a mean score of 77. At 2 weeks, the DASH had improved to a mean of 57, at 4 to 6 weeks to a mean of 37, at 3 months to a mean of 21, and at 1 year to a mean of 9 (Fig. 1). The PRWHE questionnaire showed similar improvement in results with a decrease in a mean score of 74 at the time of the fracture to a mean of 11 at 1 year follow-up (Fig. 2).

### Adverse events

There were 2 patients reporting radial nerve complaints after surgery. One of these patients was treated with a neurolysis at 8 weeks. Both reported complete resolution of symptoms at the 12-week follow-up.



**FIGURE 1:** The DASH score is seen to improve over 1 year with the greatest improvement seen between the 2-week and the 4- to 6-week period.

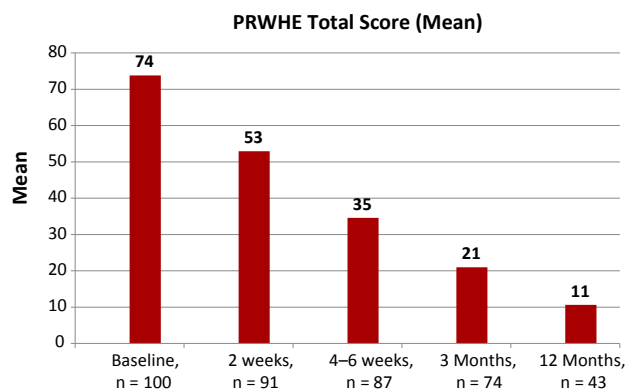
Three patients developed pain associated with prominent screws during the healing period. All 3 patients reported complete resolution of symptoms following removal of 1 or more of the prominent screws after fracture healing. None of the devices required removal.

### Range of motion

Wrist flexion and extension, radial and ulnar deviation, and pronation and supination were measured with motion expressed in terms of a percentage of the uninjured extremity with the exception of the 1 patient with bilateral wrist fractures. Figure 3 shows that, on average, flexion and extension measured about 50% of normal at 2 weeks and had improved to about 75% of normal by 12 weeks. Radial and ulnar deviation measured close to 60% at 2 weeks and had improved to 78% by 12 weeks. Pronation and supination improved to 88% of normal at 2 weeks and 95% at 12 weeks. Range of motion continued to improve up to 1 year, but the majority of improvement was seen in the first 12 weeks.

### Radiographic evaluation

X-rays taken before surgery, immediately after surgery, and at intervals up to 1 year were closely evaluated. Table 2 illustrates that most fractures were displaced with a loss of radial inclination and normal volar tilt before surgery. There was also often radial shortening as measured by increased ulnar variance.<sup>15</sup> Coronal shift of the fracture was seen in some instances. These deformities were all corrected back to normal or near-normal anatomical parameters at the time of surgery with some surgeons choosing, when they could not get an anatomical reduction with closed methods, to accept some radial shortening and



**FIGURE 2:** PRWHE score is seen to improve gradually over 1 year.

lack of complete restoration of normal volar tilt because of the patient's age or compromised medical condition. The reduction obtained and accepted at the time of surgery was maintained throughout fracture healing.

Early callus formation was seen at the fracture site in 7.5% of cases at 2 weeks and in 87.5% of cases at 4 to 6 weeks. All fractures were healed at 12 weeks (Fig. 4).

## DISCUSSION

Over the past decade, the operative management of distal radius fractures has moved from dorsal plating and fragment-specific fixation to the widespread use of volar plates for the reduction and treatment of simple and complex fractures. Volar plating offers several advantages over other techniques, including visualization of the volar fracture fragments and ease of plate application; however, complications such as tendon rupture, transient nerve injuries, and post-operative stiffness associated with plate placement, screw placement, and pronator quadratus stripping may occur.<sup>11-13,16,17</sup>

Intramedullary fixation of distal radial fractures, through a minimal approach utilizing a nail, has been used with successful outcomes. However, this technique does not allow for screw fixation of separate fracture fragments to the nail construct and is best reserved for simple A-type fractures.<sup>17-21</sup>

The intramedullary cage that has been shown to be biomechanically equivalent to volar plates was designed to be inserted in a collapsed state and then expanded to fill a spot created with a cavity preparation device in the subcortical region of the distal radius just proximal to the distal radial fracture.<sup>22</sup> By inserting the device in a collapsed state, the procedure may be less invasive than traditional open plating. The device itself

is not intended to be used to reduce a distal radial fracture but to stabilize the fracture once a reduction has been obtained through conventional methods. In this study, the device was not used for treating highly comminuted fractures such as AO class C3.

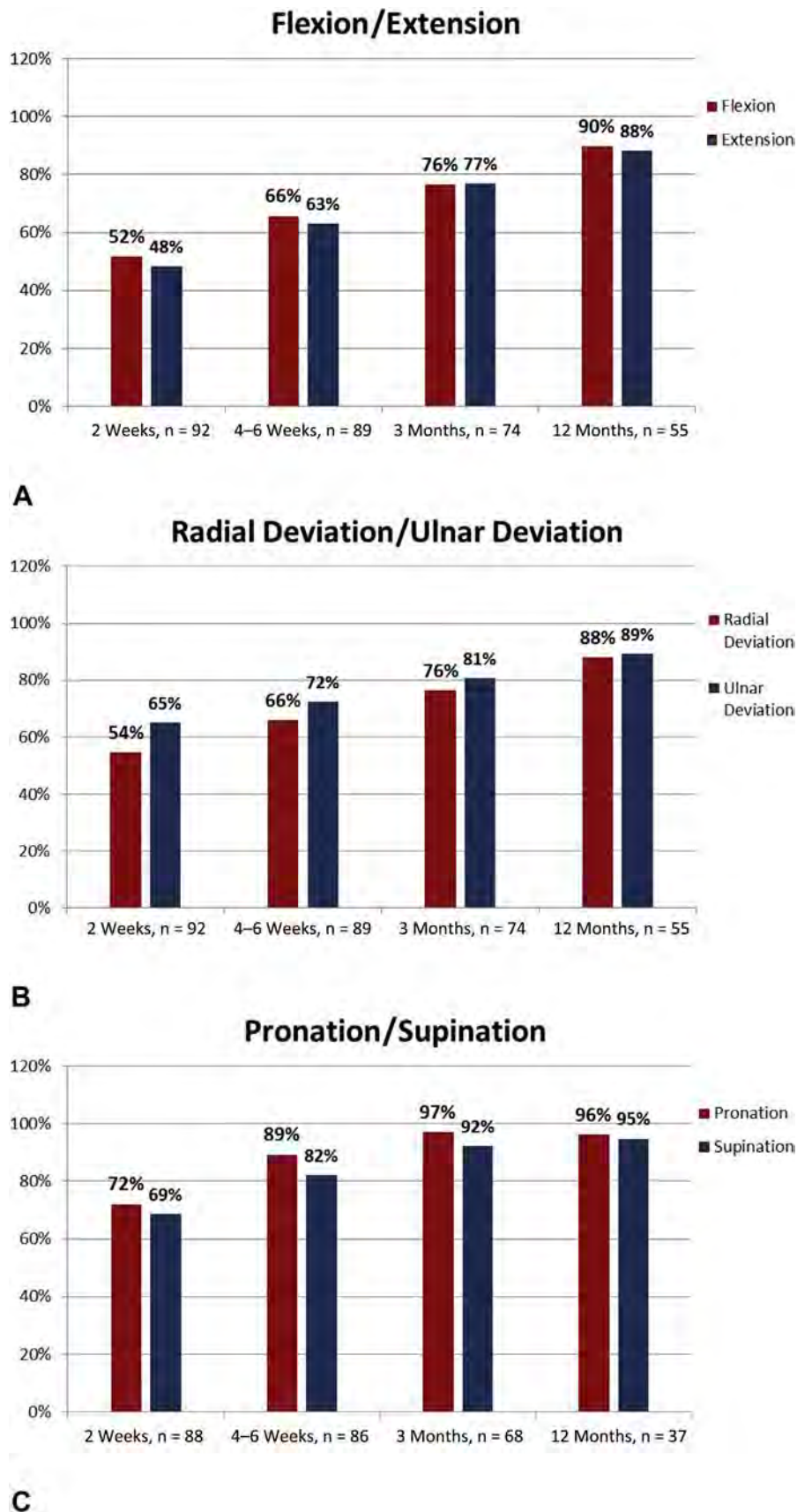
The advantages of the technique presented here include a small incision, minimal periosteal stripping, intramedullary placement of the fixation construct, and the ability for the surgeon to choose the number and direction of screws used to hold fracture fragments to the construct.

The mean DASH and total PRWHE scores for all subjects for whom 12-week follow-up was obtained ( $n = 73$ ) were very similar, with both being reported at 21. For those for whom there was follow-up of 1 year ( $n = 47$ ), mean DASH was 9 and total PRWHE was 11. For both DASH and PRWHE, the biggest improvement was seen in the first 12 weeks following treatment. These findings compare favorably with reports in the literature and are similar to those seen with other devices for distal radial fracture fixation.<sup>21,23-33</sup>

A total of 5 subjects (5 of 100; 5%) experienced an adverse event related to the device and/or procedure. Two subjects experienced radial nerve symptoms and 3 subjects reported tendon irritation associated with 1 or more of the fragment-specific screws. The symptoms resolved after removal of the prominent screws in all cases. These adverse events are also seen with all other forms of internal fixation for distal radial fractures, although the incidence of 5% for adverse events associated with this device is lower than that reported with other forms of internal fixation.<sup>9-13</sup> To lessen the occurrence of radial nerve problems, we now recommend that the self-retaining retractor used in the radial incision be removed as soon as possible during the procedure. To prevent problems associated with prominent screws, we now recommend that a cut-down incision be done in conjunction with placement of each screw and that the head of each screw can be buried in the bone.

In this series, there were no reported occurrences of infections, device failure necessitating device removal, or carpal tunnel syndrome. Such complications have been reported with other forms of internal fixation, ranging from 14% to 22%.<sup>9-13,18,34,35</sup>

Although there were no device removals in this study, there have been cases in which the implant has been removed. In Germany, health care practitioners routinely remove metallic and other implants if they are of no additional benefit to the patient. The intramedullary device and screws have been removed up to 444 days after insertion as requested by the patient.

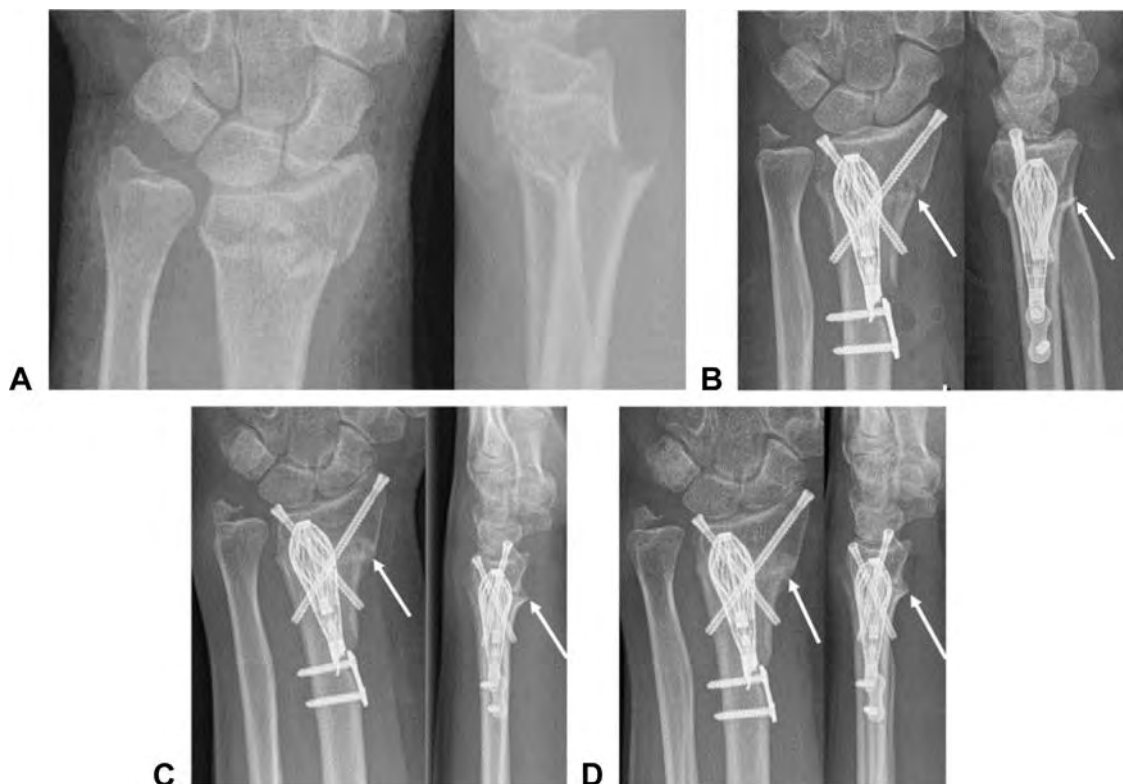

**FIGURE 3: A** Range of motion of the injured wrist compared with the uninjured wrist improved with time in flexion/extension. **B** Radial/ulnar deviation. **C** Pronation/supination.

**TABLE 2. Radiographic Data**

Statistic	Preoperative	Postoperative	2 Wk	4-6 Wk	12 Wk	12 Mo
<b>Radial Inclination (°)</b>						
Mean	16.5	19.9	19.6	19.6	19.7	19.7
Range	2–22	15–22	15–22	14–22	14–22	14–22
<b>Volar Tilt (°)</b>						
Mean*	+13.1	–1.5	–1.8	–1.3	–1.2	–1.4
Range*	–5 to +38	–5 to +5	–5 to +6	–5 to +6	–5 to +6	–5 to +6
<b>Ulnar Variance (mm)</b>						
Mean*	+1.5	+0.1	+0.5	+0.5	+0.4	+0.5
Range*	–2 to +5	–2 to +4	–2 to +4	–2 to +4	–2 to +4	–2 to +4
<b>Evidence of Fracture Healing</b>						
Baseline	Postoperative	2 Wk	4-6 Wk	12 Wk		
NA	NA	7.5% (3 of 40)	87.5% (35 of 40)	100% (40 of 40)		

\*– refers to degrees less than neutral and + refers to degrees more than neutral.



**FIGURE 4:** **A** Two views of a dorsally comminuted, displaced, and angulated extra-articular distal radial fracture. **B** The expandable cage and 2 fragment fixation screws in place at the time of surgery. The arrows show the fracture line. **C** Early healing radially 4 to 6 weeks after surgery. The arrows show the fracture line with presence of callus formation. **D** Healing of the fracture (arrows) at 3 months after surgery.

In each case, the device was able to be removed without causing additional damage to surrounding tissues.

Radiographic follow-up in this study revealed that the intramedullary device and fragment-specific screw fixation resulted in a stable fracture construct as evidenced by minimal or no change in position of the postoperative reduction throughout healing (Table 2). Full healing of the fracture was seen in 100% of cases at 12 weeks as well as early signs of healing in 87% of cases at 4 to 6 weeks. Because cavity preparation for the implant essentially creates a bone slurry from the intramedullary bone while removing no bone, it is possible that an osteogenic milieu is created that contributes to rapid fracture healing. Further study of this is required.

The study shows that an expandable intramedullary implant with fragment-specific screw fixation has been associated with satisfactory results and a low complication rate when used for treating distal radius fractures, with the exception of AO class C3 fractures.

## REFERENCES

- Singer BR, McLaughlan GJ, Robinson CM, Christie J. Epidemiology of fractures in 15000 adults: the influence of age and gender. *J Bone Joint Surg Br.* 1998;80(2):243–248.
- Court-Brown CM, Caesar B. Epidemiology of adult fractures: a review. *Injury.* 2006;37(8):691–697.
- Chung KC, Spilson SV. The frequency and epidemiology of hand and forearm fractures in the United States. *J Hand Surg Am.* 2001;26(5):908–915.
- Lofthus CM, Frihagen F, Meyer HE, Nordsletten L, Melhuus K, Falch JA. Epidemiology of distal forearm fractures in Oslo. *Norway. Osteoporos Int.* 2008;19(6):781–786.
- Chung KC, Shauver MJ, Birkmeyer JD. Trends in the United States in the treatment of distal radius fractures in the elderly. *J Bone Joint Surg Am.* 2009;91(8):1868–1873.
- Koval KJ, Harrast JJ, Anglen JO, Weinstein JN. Fractures of the distal radius: the evolution of practice over time. Where's the evidence? *J Bone Joint Surg Am.* 2008;90(9):1855–1861.
- Jupiter JB. Fractures of the distal end of the radius. *J Bone Joint Surg Am.* 1991;73(3):461–469.
- Orbay JL, Fernandez DL. Volar fixed-angle plate fixation for unstable distal radius fractures in the elderly patient. *J Hand Surg Am.* 2004;29(1):96–102.
- Arora R, Lutz M, Hennerbichler A, Krappinger D, Espen D, Gabl M. Complications following internal fixation of unstable distal radius fracture with a palmar locking plate. *J Orthop Trauma.* 2007;21(5):316–322.
- Jupiter JB, Marent-Huber M, LCP Study Group. Operative management of distal radial fractures with 2.4-millimeter locking plates: a multicenter prospective case series. *J Bone Joint Surg Am.* 2009;91(1):55–65.
- Williksen JH, Husby T, Hellund JC, Kvermmo HD, Rosales C, Frihagen F. External fixation and adjuvant pins versus volar locking plate fixation in unstable distal radius fractures: a randomized, controlled study with a 5-year follow-up. *J Hand Surg Am.* 2015;40(7):1333–1340.
- Knudsen R, Bahadirov Z, Damborg F. High rate of complications following volar plating of distal radius fractures. *Dan Med J.* 2014;61(10):A4906.
- Matzon JL, Kenniston J, Beredjiklian PK. Hardware-related complications after dorsal plating for displaced distal radius fractures. *Orthopedics.* 2014;37(11):e978–e982.
- Rozental TD, Blazar PE, Franko OI, Chacko AT, Earp BE, Day CS. Functional outcomes for unstable distal radial fractures treated with open reduction and internal fixation or closed reduction and percutaneous fixation. A prospective randomized trial. *J Bone Joint Surg Am.* 2009;91(8):1837–1846.
- Graham TJ. Surgical Correction of malunited fractures of the distal radius. *J Am Acad Orthop Surg.* 1997;5(5):270–281.
- Roh YH, Lee BK, Baek JR, Noh JH, Gong HS, Baek GH. A randomized comparison of volar plate and external fixation for intra-articular distal radius fractures. *J Hand Surg Am.* 2015;40(1):34–41.
- Gunther SB, Lynch TL. Rigid internal fixation of displaced distal radius fractures. *Orthopedics.* 2014;37(1):e34–e38.
- Gradl G, Mielsch N, Wendt M, et al. Intramedullary nail versus volar plate fixation of extra-articular distal radius fractures. Two year results of a prospective randomized trial. *Injury.* 2014;45(Suppl 1):S3–S8.
- Tan V, Bratchenko W, Nourbakhsh A, Capo J. Comparative analysis of intramedullary nail fixation versus casting for treatment of distal radius fractures. *J Hand Surg Am.* 2012;37(3):460–468.
- Safi A, Hart R, Těknědžjan B, Kozák. Treatment of extra-articular and simple articular distal radial fractures with intramedullary nail versus volar locking plate. *J Hand Surg Eur Vol.* 2013;38(7):774–779.
- Schönnemann JO, Hansen TB, Søballe K. Randomised study of non-bridging external fixation compared with intramedullary fixation of unstable distal radial fractures. *J Plast Hand Surg.* 2011;45(4–5):232–237.
- van Kampen RJ, Thoreson AR, Knutson NJ, Hale JE, Moran SL. Comparison of a new intramedullary scaffold to volar plating for treatment of distal radius fractures. *J Orthop Trauma.* 2013;27(9):535–541.
- Capo JT, Hashem J, Orillaza NS, Tan V, Warburton M, Bonilla L. Treatment of extra-articular distal radial malunions with an intramedullary implant. *J Hand Surg Am.* 2010;35(6):892–899.
- Egol K, Walsh M, Tejwani N, McLaurin T, Wynn C, Paksima N. Bridging external fixation and supplementary Kirschner-wire fixation versus volar locked plating for unstable fractures of the distal radius: a randomised, prospective trial. *J Bone Joint Surg Br.* 2008;90(9):1214–1221.
- Ilyas AM, Thoder JJ. Intramedullary fixation of displaced distal radius fractures: a preliminary report. *J Hand Surg Am.* 2008;33(10):1706–1715.
- Marcheix PS, Dotzis A, Benkö PE, Siegler J, Arnaud JP, Charissoux JL. Extension fractures of the distal radius in patients older than 50: a prospective randomized study comparing fixation using mixed pins or a palmar fixed-angle plate. *J Hand Surg Eur Vol.* 2010;35(8):646–651.
- McFadyen I, Field J, McCann P, Ward J, Nicol S, Curwen C. Should unstable extra-articular distal radial fractures be treated with fixed-angle volar-locked plates or percutaneous Kirschner wires? A prospective randomised controlled trial. *Injury.* 2011;42(2):162–166.
- van Manen CJ, Dekker ML, van Eerten PV, Rhemrev SJ, van Olden GD, van der Elst M. Bio-resorbable versus metal implants in wrist fractures: a randomised trial. *Arch Orthop Trauma Surg.* 2008;128(12):1413–1417.
- Wei DH, Raizman NM, Bottino CJ, Jobin CM, Strauch RJ, Rosenwasser MP. Unstable distal radial fractures treated with external fixation, a radial column plate, or a volar plate. A prospective randomized trial. *J Bone Joint Surg Am.* 2009;91(7):1568–1577.

30. Wilcke MK, Abbaszadegan H, Adolphson PY. Wrist function recovers more rapidly after volar locked plating than after external fixation but the outcomes are similar after 1 year. *Acta Orthop*. 2011;82(1):76–81.
31. Hunsaker FG, Cioffi DA, Amadio PC, Wright JG, Caughlin B. The American Academy of Orthopaedic Surgeons Outcome Instruments. Normative values from the general population. *J Bone Joint Surg Am*. 2002;84(2):208–215.
32. Lauder A, Agnew S, Bakri K, Allan CH, Hanel DP, Huang JI. Functional outcomes following bridge plate fixation for distal radius fractures. *J Hand Surg Am*. 2015;40(8):1554–1562.
33. Costa ML, Achten J, Parsons NR, et al. Volar locking-plate and Kirschner-wire fixation did not differ in terms of functional outcomes after dorsally displaced distal radial fracture. *J Bone Joint Surg Am*. 2015;97A(10):859.
34. McKay SD, MacDermid JC, Roth JH, Richards RS. Assessment of complications of distal radius fractures and development of a complication checklist. *J Hand Surg Am*. 2001;26(5):916–922.
35. Davis DI, Baratz M. soft tissue complications of distal radius fractures. *Hand Clin*. 2010;26(2):229–235.